

Lidiia Levytska, Iryna Nezgoda

Received: 18.06.2021

Accepted: 27.01.2022

Published: 31.05.2021

## Varicella with secondary skin bacterial complications: case reports

### Ospa wietrzna z wtórnymi powikłaniami bakteryjnymi skóry: opisy przypadków

Department of Paediatric Infectious Diseases, National Pirogov Memorial Medical University, Vinnytsia, Ukraine  
Correspondence: Lidiia Levytska, Lyali Ratushnoi St. 16#5, Vinnytsia, Ukraine, tel.: +380963467883, e-mail: flup2401@gmail.com

#### ORCID iDs

1. Lidiia Levytska <https://orcid.org/0000-0002-7622-8859>

2. Iryna Nezgoda <https://orcid.org/0000-0002-7925-3398>

#### Abstract

Chickenpox is a very contagious childhood disease with a self-limited course. It is most common in children up to 10 years old, but can infect a person at any age. Varicella presents with itchy pseudo-polymorphic rash (macula, papula, vesicle, crust) and mild intoxication syndrome. The disease is benign and uncomplicated in general, but complications can occur regardless of immune status and concomitant diseases. Neurological and respiratory are among the most common complications. In the patients described in this article, we can observe secondary bacterial superinfection (pyoderma and phlegmon). These are the third most common complications of varicella, and may have serious consequences. These cases are presented to call attention to proper skincare in a patient with chickenpox and to the choice of an appropriate antipyretic to control fever. It is also important to emphasise the importance of vaccination against this disease and to combat the misconceptions of anti-vaxxers.

**Keywords:** varicella, chickenpox, complication, pyoderma, phlegmon

#### Streszczenie

Ospa wietrzna jest wysoce zaraźliwą chorobą wieku dziecięcego o samoograniczającym się przebiegu. Choć najczęściej występuje u dzieci do 10. roku życia, może dotyczyć osób w każdym wieku. Ospa wietrzna objawia się swędzącą wysypką pseudopolimorficzną (plamki, grudki, pęcherzyki, strupy) oraz łagodnym zespołem intoksykacji. Choroba przebiega na ogół łagodnie i bez powikłań, które mogą jednak wystąpić niezależnie od statusu immunologicznego i chorób współistniejących pacjenta. Najczęstsze powikłania dotyczą układu nerwowego i oddechowego. W przedstawionej pracy opisano przypadki pacjentów, u których zaobserwowano wtórne nadkażenie bakteryjne (piodermię i ropowicę). Są to trzecie co do częstości powikłania ospy wietrznej, które mogą mieć poważne konsekwencje. Przypadki te przedstawiono w celu zwrócenia uwagi na właściwą pielęgnację skóry oraz wybór odpowiedniego leku przeciwgorączkowego u pacjenta z ospą wietrzną. Ważne jest również podkreślenie znaczenia szczepień przeciwko tej chorobie i zwalczanie błędnych wyobrażeń wśród antyszczepionkowców.

**Słowa kluczowe:** ospa wietrzna, powikłania, piodermia, ropowica

## INTRODUCTION

Varicella is an acute ubiquitous infectious disease caused by a DNA virus of the *Herpesviridae* family. It is a very contagious disease. The course of chickenpox is benign, self-limited, and generally uncomplicated<sup>(1)</sup>. The incidence rate of varicella varies across the world. Incidence rates are decreased in countries with regular vaccination practices, but still remain high in countries without such practices. The vaccine against varicella is live (attenuated). It is profoundly effective in inducing a persistent immune response and giving long-term protection against potential breakthrough varicella-zoster virus (VZV) infections<sup>(2)</sup>. In Ukraine, the vaccine is recommended, but is not included in the national vaccination schedule. For this reason, the morbidity rate over the years is still high (Fig. 1). The severity of complications was previously thought to depend on the patients' immune status and comorbidities. A significant role in the pathogenesis of chickenpox, particularly in the activation of cellular immunity, is played by T-lymphocytes (or T-cells)<sup>(3)</sup>. In immunocompetent and most immunocompromised persons, antibodies and VZV-specific T cells are generated during primary infection and often protect against symptomatic reinfections after new exposure. Antibodies to VZV are likely to be the first line of defence against a new respiratory mucosal inoculation of the virus, whereas VZV-specific T-cell responses are most important. T-cell-mediated immunity declines with age beyond mid-adulthood, and a considerable reduction in VZV-specific early effectors and cytokine-producing CD4+ and CD8+ T-cells increases the likelihood of latent viral reactivation<sup>(4)</sup>. A research in immunocompromised individuals with T-cell defects found that they are at increased risk of specific VZV complications and secondary superinfection<sup>(5)</sup>. In immunocompromised children, complications

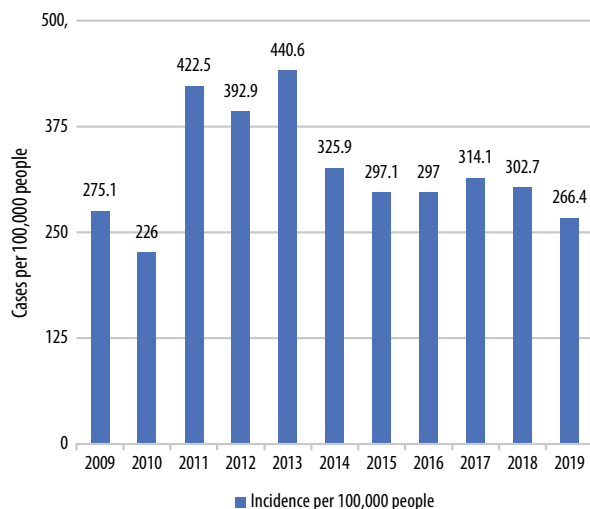


Fig. 1. Varicella incidence in the years 2009–2019, according to data from the Center of Public Health of Ukraine (obtained in an official letter from the Center of Public Health)

may occur in every 2 to 3 patients. But even previously healthy persons may develop severe varicella and experience various kinds of complications. Overall, complications occur in about 4 to 9% of cases of varicella<sup>(6)</sup>. Before the implementation of regular vaccinations, Europe had more than 5 million cases of varicella every year, with more than 3 million primary care consultations per year, about 20 thousand hospitalisations per year, and up to 80 deaths per year (95% confidence interval, CI: 19–822). Of these cases, 60% were seen in youngsters under the age of 5 years (95% CI: 2.7–3.3). Yearly incidence per 100,000 population as per reports differed between Western (the United Kingdom, France, Germany, and the Netherlands), Southern (Italy, Portugal, Spain) and Eastern (Romania, Poland) Europe as 300–1291, 164–1240 and 350, respectively. Hospitalisations and deaths are more frequent in children under the age of 4 years<sup>(7)</sup>. Specific complications related to VZV include neurological (cerebellar ataxia, encephalitis, aseptic meningitis, transverse myelitis, Guillain–Barré syndrome), respiratory (laryngotracheitis, bronchitis, pneumonitis), and other complications (anicteric hepatitis, pancreatitis, nephritis, orchitis, thrombocytopenic purpura, myocarditis, pericarditis). Secondary superinfection may lead to otitis media, bacterial pneumonia, skin infections (pyoderma, phlegmon, cellulitis, necrotizing fasciitis), and osteomyelitis<sup>(8)</sup>. Pyoderma and impetigo are synonyms. Serious bacterial soft tissue infections are caused by the group of A streptococci or *Staphylococcus aureus* generally, which can produce exotoxins and cause local tissue destruction<sup>(9,10)</sup>. Bullous impetigo is caused by *S. aureus* strains that release a toxin that causes the dermal-epidermal border to cleave, creating fragile, thin-walled vesicopustules. Infections with streptococci or *S. aureus*, or both in combination, can cause nonbullous impetigo<sup>(11)</sup>. The therapy of varicella-associated necrotizing fasciitis consists of early and aggressive surgical debridement, appropriate antibiotic therapy, and intensive supportive care. Adjunctive therapy with intravenous immunoglobulins may also be beneficial in patients with necrotizing fasciitis and streptococcal toxic shock syndrome<sup>(12)</sup>. Some authors have considered a potential connection between the increased risk of varicella-associated necrotizing fasciitis and the use of non-steroidal anti-inflammatory drugs (NSAIDs) (such as ibuprofen). But this remains dubious<sup>(13)</sup>. Regardless, it appears to be prudent to avoid NSAIDs and to choose other medications (e.g. acetaminophen) to help control fever in patients with varicella. Our study aims to present the clinical course of complicated varicella with secondary superinfection of the skin (pyoderma, phlegmon) and consider ways to prevent this.

## CASE REPORT

In the period from 2016 to 2020, a total of 130 patients with chickenpox were hospitalised at the Vinnytsia Regional Infectious Paediatric Hospital in Ukraine. A complicated course of disease appeared in 31.5% (41 patients). The most

frequent complications were neurological, which were reported in 18 children (13.8%); cerebellitis ( $n = 10$ ), cerebellar ataxia ( $n = 6$ ), and meningoencephalitis ( $n = 2$ ). Pneumonia was present in 10 (24.4%), superinfection of the skin and soft tissue in 6 (14.6%), gastrointestinal complications in 6 (14.6%), and arthritis and thrombocytopenic purpura in 1 (4.2%) patient. *Streptococcus pyogenes* was the leading cause of bacterial infections in 4 cases (14.6%). All 6 patients with bacterial infections under observation were previously healthy, without comorbidities. There were 5 girls and 1 boy.

### Case 1. Patient with pyoderma

A 4-year girl was admitted to the Vinnytsia Regional Infectious Paediatric Hospital due to a fever of 39.2°C, rash, weakness, loss of appetite, and severe pruritus. She was sick for 6 days with a maculopapular, vesicular rash.

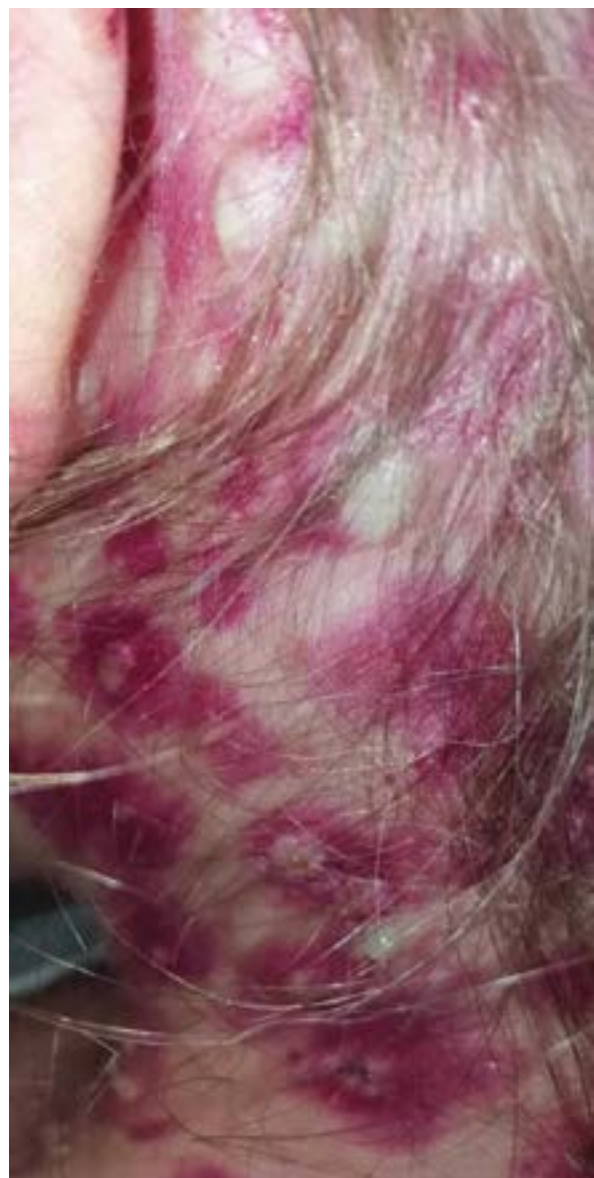

Fig. 2. Pustules behind the ear on the day of admission

New elements of the rash appeared over the course of the 6 days. Also, on day 5 some elements underwent a colour change, becoming whitish and opaque. Her temperature was 37–37.8°C during the first 4 days, and then increased to 38.9–39.5°C. She was examined by a family doctor at the onset of the illness and isolated at home with supportive treatment (she took ibuprofen for her fever, at a dose of 10 mg/kg at a time every 7–8 hours for 2 days and applied fucorcin as topical treatment). Her general state deteriorated, and the girl was hospitalised. The epidemiological history: several of her kindergarten classmates had been sick with varicella. She had not been vaccinated against this disease and had not been infected with it previously. On admission, the patient had moderate symptoms. Physical examination revealed an exanthema over the body (trunk, extremities, scalp, face, palms, and feet) and an enanthema (the mucous membranes). The elements of rash were pustules with surrounding local redness, vesicles predominantly over the body, and some additional elements were honey-coloured crusts on an erythematous base. The largest elements could be seen behind the ear (Fig. 2). In addition, erosion was present on the mucous membranes of the oral cavity. Examination of the respiratory and cardiac systems and abdomen revealed no abnormalities. There were no meningeal or focal signs. The anterior and posterior cervical lymph nodes were enlarged. Laboratory findings included: white blood cells (WBC)  $17.8 \times 10^9/L$ , erythrocyte sedimentation rate (ESR) 32 mm/h, segments 72%, C-reactive protein (CRP) 12 mg/mL (positive). The urine test was normal. Varicella was confirmed by a positive IgM VZV result from an ELISA kit and the presence of VZV DNA found through PCR in swabs of vesicular lesions. A bacteriological investigation from the pustular lesions revealed the growth of *Streptococcus pyogenes*. The patient was treated with IV acyclovir at 10 mg/kg at a time every 6 hours for 3 days and then orally for 2 days. The antibiotic treatment was ceftriaxone, 50 mg/kg/day by IV for 5 days.

During treatment, new elements of the rash stopped appearing on day 3 (day 9 of the disease). The pustular elements dried up entirely, leaving discoloration and small scars predominantly where the elements were bigger. The symptoms subsided over 5 days and the girl was discharged.

### Case 2. Patient with phlegmon

A 5-year-old boy was admitted to the same hospital with a papulo-vesicular-pustular rash all over his body, fever, and redness; as well as oedema of the skin of the lateral part of the thorax, increased local temperature, and pain. He was sick at home for 5 days, without having been examined by a doctor. Pustular elements of the rash had appeared 1 day before. His mother applied brilliant green and reduced his fever of 38.9°C with ibuprofen, at a dose of 10 mg/kg at a time every 8 hours over the last 4 days at

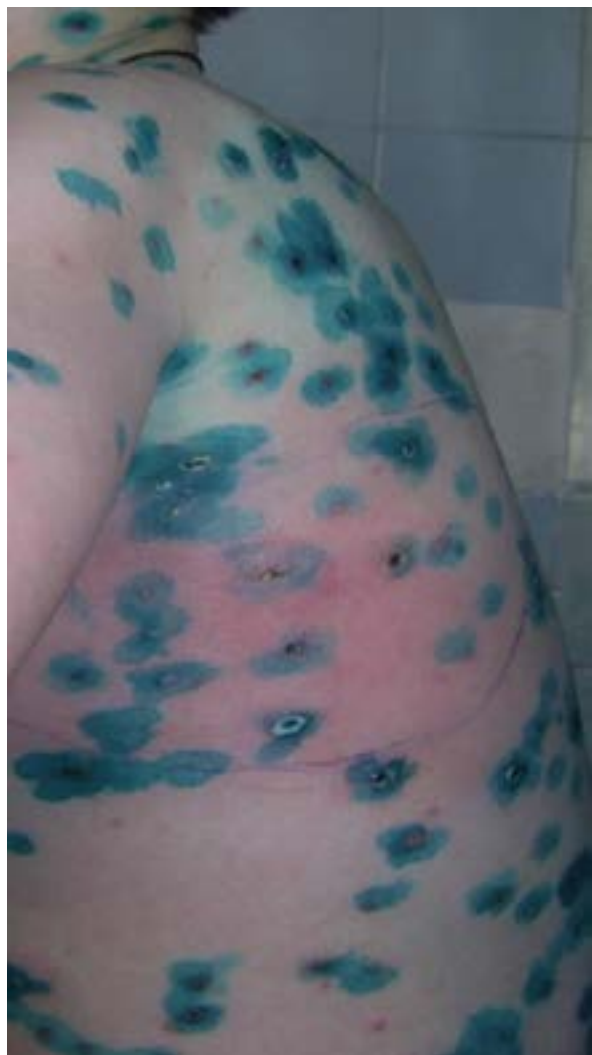

Fig. 3. Phlegmon and pustules of the lateral thoracic side on the day of admission

home. Redness of the skin appeared in the morning, and the boy was admitted to the hospital (Fig. 3). He was not vaccinated against varicella, and had no immune suppression or comorbidities. The boy had contact with a friend with chickenpox 14 days before developing symptoms. The patient was examined by a surgeon and transferred to the Regional Paediatric Hospital for further treatment. The results of the laboratory investigations were as follows: WBC  $19.6 \times 10^9/L$ , ESR 38 mm/h, segments 76%, CRP (C-reactive protein) 36 mg/mL (positive). Varicella was confirmed by a positive IgM VZV result from an ELISA kit. Other laboratory tests were not performed to confirm the aetiology. In the surgical department, treatment consisted of surgical incisions to stop the spread of the pathological process, and prescription of antibiotics (ceftriaxone 50 mg/kg/day by IV for 10 days, amikacin 15 mg/kg/day by IV for 7 days). Acyclovir was not prescribed. The patient spent 14 days in the surgical department. The boy was discharged with severe scarring of the lateral part of the thorax (Fig. 4).

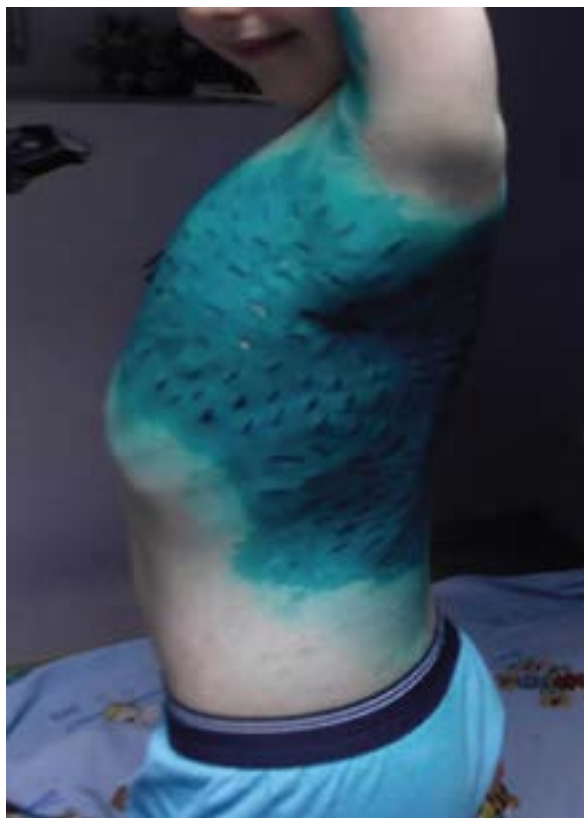

Fig. 4. Severe scarring after surgical treatment of phlegmon caused by varicella in a 5-year-old patient

## DISCUSSION

Varicella is a very common, infectious, benign childhood disease. Ukraine is a country without obvious varicella vaccination and the majority of all cases occur between the ages of 3 and 10 years. The disease starts with a mild to moderate fever and the appearance of a typical pseudo-polymorphic rash (macula, papula, vesicle, crust) without scarring. The disease is self-limited and clinical manifestations are sufficient for diagnosis in previously healthy children. However, complications may occur even without any immune suppression or comorbidities. One of the most common problems is secondary bacterial superinfection. Pruritus following rash in chickenpox compels the patient to scratch the rash. In the case of poor hygiene (sweat on the body, untrimmed nails) this itching can result in infection. Studying the composition of the microbiota allowed us to conclude that skin disorders happen when the biofilm is damaged. When the balance between the commensals and pathogens is disturbed, skin disease can arise<sup>(14)</sup>. This primarily includes diseases caused by *Streptococcus* and *Staphylococcus aureus* bacteria. They are a prominent cause of skin and soft tissue damage. Staphylococcal toxins have suppurative, exfoliative, and superantigenic effects. This data should be taken into consideration for the management of infectious processes; clindamycin could be used as an antibiotic with toxin-targeting effects in children

with varicella<sup>(15)</sup>. On the other hand, the Infectious Diseases Society of America recommends IV antibiotics such as penicillin, clindamycin, cefazolin, and cephalexin for a typical course of cellulitis with systemic signs<sup>(11)</sup>. Both of our patients were put on ceftriaxone. We need to consider antimicrobials that are active against streptococci. Bacteriological investigation of blood or cutaneous suction is not regularly suggested but could be recommended for patients with immunodeficiency or neutropenia.

Some studies reported an increased risk of invasive streptococcal infection associated with ibuprofen therapy. Ibuprofen was given to both of our patients to reduce fever. Mikaeloff et al. conducted a 12-year epidemiological case-control study based on a cohort of 140,111 patients with chickenpox to see if there was a link between chickenpox and severe soft tissue complications. The use of NSAIDs may increase the risk of serious skin problems<sup>(13)</sup>.

In our patients, scarring manifested more severely in patients with phlegmon.

None of the patients was vaccinated against varicella. It was reported that 1 dose of the vaccine offers 84.5% protection against varicella and more than 95% effectiveness against the severe form<sup>(16)</sup>. We need to recommend vaccination for both healthy and immunocompromised persons and inform parents about the effectiveness of vaccines and the danger of complicated forms of the disease.

## CONCLUSION

Varicella may be complicated with secondary bacterial infections of the skin such as pyoderma and phlegmon. The occurrence of complications depends on the immune status of the host, but they can appear in both immunocompromised and healthy individuals. In the case of fever, patients should avoid NSAIDs as much as possible, but in cases of extreme need, paracetamol should be selected. The choice of proper antibiotic is between penicillin, clindamycin, cefazolin, and cephalexin. Vaccination is the best option to prevent this disease, including its severe form.

### Conflict of interest

*Authors do not report any financial or personal connections with other persons or institutions, that might claim authorship rights to this publication.*

## References

1. Sauerbrei A: Diagnosis, antiviral therapy, and prophylaxis of varicella-zoster virus infections. *Eur J Clin Microbiol Infect Dis* 2016; 35: 723–734.
2. Vessey SJ, Chan CY, Kuter BJ et al.: Childhood vaccination against varicella: persistence of antibody, duration of protection, and vaccine efficacy. *J Pediatr* 2001; 139: 297–304.
3. Gershon M, Gershon A: Varicella-zoster virus and the enteric nervous system. *J Infect Dis* 2018; 218 (suppl\_2): S113–S119.
4. Arvin AM, Wolinsky JS, Kappos L et al.: Varicella-zoster virus infections in patients treated with fingolimod: risk assessment and consensus recommendations for management. *JAMA Neurol* 2015; 72: 31–39.
5. Ziebold C, von Kries R, Lang R et al.: Severe complications of varicella in previously healthy children in Germany: a 1-year survey. *Pediatrics* 2001; 108: E79. Erratum in: *Pediatrics* 2004; 113: 1470.
6. Bonhoeffer J, Baer G, Muehleisen B et al.: Prospective surveillance of hospitalisations associated with varicella-zoster virus infections in children and adolescents. *Eur J Pediatr* 2005; 164: 366–370.
7. Varela FH, Pinto LA, Scotta MC: Global impact of varicella vaccination programs. *Hum Vaccin Immunother* 2019; 15: 645–657.
8. Gnann JW Jr: Varicella-zoster virus: atypical presentations and unusual complications. *J Infect Dis* 2002; 186 Suppl 1: S91–S98.
9. Laupland KB, Davies HD, Low DE et al.: Invasive group A streptococcal disease in children and association with varicella-zoster virus infection. Ontario Group A Streptococcal Study Group. *Pediatrics* 2000; 105: E60.
10. Lesko SM, O'Brien KL, Schwartz B et al.: Invasive group A streptococcal infection and nonsteroidal antiinflammatory drug use among children with primary varicella. *Pediatrics* 2001; 107: 1108–1115.
11. Stevens DL, Bisno AL, Chambers HF et al.; Infectious Diseases Society of America: Practice guidelines for the diagnosis and management of skin and soft tissue infections: 2014 update by the Infectious Diseases Society of America. *Clin Infect Dis* 2014; 59: e10–e52.
12. Cawley MJ, Briggs M, Haith LR Jr et al.: Intravenous immunoglobulin as adjunctive treatment for streptococcal toxic shock syndrome associated with necrotizing fasciitis: case report and review. *Pharmacotherapy* 1999; 19: 1094–1098.
13. Quaglietta L, Martinelli M, Staiano A: Serious infectious events and ibuprofen administration in pediatrics: a narrative review in the era of COVID-19 pandemic. *Ital J Pediatr* 2021; 47: 20.
14. Lunjani N, Hlela C, O'Mahony L: Microbiome and skin biology. *Curr Opin Allergy Clin Immunol* 2019; 19: 328–333.
15. Raulin O, Durand G, Gillet Y et al.: Toxin profiling of *Staphylococcus aureus* strains involved in varicella superinfection. *J Clin Microbiol* 2010; 48: 1696–1700.
16. Marin M, Meissner HC, Seward JF: Varicella prevention in the United States: a review of successes and challenges. *Pediatrics* 2008; 122: e744–e751.