

Aranjit Singh Randhawa^{1,2}, Anusha Balasubramaniam³, Philip Rajan³, Irfan Mohamad²

Migratory foreign body in the neck

Przemieszczające się ciało obce w obrębie szyi

¹ Department of Otorhinolaryngology, Hospital Teluk Intan, Jalan Changkat Jong, 36000 Teluk Intan, Perak, Malaysia

² Department of Otorhinolaryngology – Head and Neck Surgery, School of Medical Sciences, Universiti Sains Malaysia Health Campus, 16150 Kota Bharu, Kelantan, Malaysia

³ Department of Otorhinolaryngology, Hospital Raja Permaisuri Bainun, Jalan Hospital, 30990 Ipoh, Perak, Malaysia

Correspondence: Associate Prof. Dr Irfan Mohamad, Department of Otorhinolaryngology, Head and Neck Surgery, School of Medical Sciences, Universiti Sains Malaysia Health Campus, 16150 Kota Bharu, Kelantan, Malaysia, tel.: +6097676420, fax: +6097676424, e-mail: irfankb@usm.com

Abstract

Ingestion of foreign body is a very common reason for referral in otolaryngology practice. In most cases, it is removed in the clinic setting or under general anaesthesia. However, migratory foreign body in the throat is rare and can cause serious complications depending on the route of migration. We present a case of a migratory fish bone, which was found embedded in the right scalene muscle and was successfully removed through an external approach. The aim of this case report is to highlight the importance of a thorough history and physical examination in a patient with a foreign body in the throat, especially if the patient is still symptomatic and laryngo-oesophagoscopy findings are unremarkable. Imaging is vital to aid in the diagnosis and precisely locating the migrated foreign body eventually to avoid fatal complications.

Keywords: migratory foreign body, neck, fish bone

Streszczenie

Ciało obce w obrębie gardła to bardzo częsty powód kierowania pacjentów do otolaryngologa. W większości przypadków ciało obce usuwane jest warunkach ambulatoryjnych lub w znieczuleniu ogólnym. Przypadki drażącego ciała obcego w gardle są rzadkie, jednak mogą wiązać się z ciężkimi powikłaniami, zależnymi od drogi migracji. W niniejszej pracy przedstawiamy przypadek przemieszczającej się rybiej ości, która została u pacjenta odnaleziona w prawym mięśniem pochyłym i z powodzeniem usunięta z dostępu zewnętrznego. Celem pracy jest podkreślenie znaczenia dokładnego wywiadu i badania przedmiotowego u osoby z ciałem obcym w gardle, w szczególności gdy pomimo negatywnego wyniku wziernikowania krtani i przełyku pacjent nadal prezentuje objawy kliniczne. Badania obrazowe mają kluczowe znaczenie dla postawienia diagnozy i określenia precyzyjnej lokalizacji ciała obcego i w ten sposób pozwalają na uniknięcie możliwych, nawet śmiertelnych powikłań.

Słowa kluczowe: przemieszczające się ciało obce, szyja, rybia ość

INTRODUCTION

Accidental ingestion of fish bone is a very common reason for referral to the otolaryngologist. It is usually easily removed by direct laryngoscopy or rigid oesophagoscopy. Occasionally they may be removed in the clinic under local anaesthetic spray if they are lodged in the oropharynx such as in the tonsil or base of tongue. In rare cases, the fish bone can migrate to soft tissues or visceral structures of the neck. Computed tomography (CT) scan of the neck is an important tool to locate the migratory foreign body.

CASE REPORT

A 37-year-old Chinese gentleman with no co-morbidity was referred complaining of pain over his right neck for 2 days. There was no associated fever, odynophagia, dysphagia, breathing difficulty or hoarseness. The patient had accidentally swallowed a fish bone 5 days prior to presentation, and had a piercing sensation over the right side of his throat ever since. He tried to dislodge the foreign body by consuming a bolus of soft food but failed. On examination, there was a sharp foreign body palpable below the skin over the lateral border of the right neck with no fluctuancy or subcutaneous emphysema (Fig. 1). Direct laryngoscopy and rigid oesophagoscopy findings were negative. Computed tomography with contrast of the neck revealed a sharp, linear foreign body piercing out from the right scalene muscle (Fig. 2).

The patient underwent right neck exploration under general anaesthesia. Intraoperatively, a sharp fish bone measuring 2 cm was found embedded in the scalene muscle (Fig. 3), lying posterior to the external jugular vein and was removed entirely (Fig. 4). Although non-purulent, the wound was washed with copious amount of diluted 10% povidone and closed primarily. He completed 5 days of intravenous cefuroxime 1.5 g TDS and metronidazole 500 mg TDS and was sent home well. He was discharged from review at 2 weeks post operatively after full recovery.

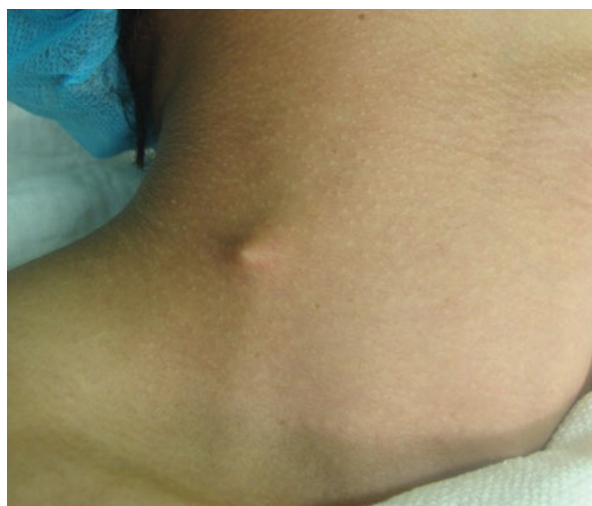

Fig. 1. Fish bone abutting the skin over the right side of the neck

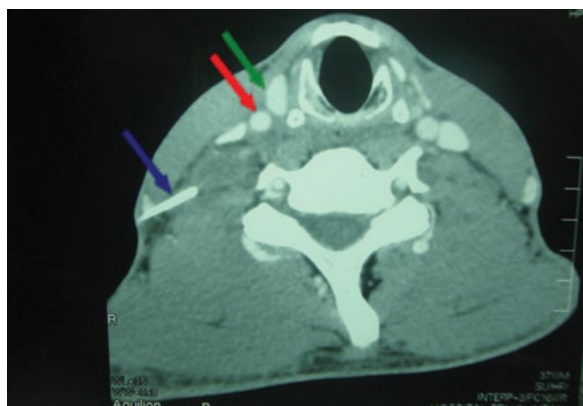


Fig. 2. Computed tomography scan showing the fish bone (blue arrow) protruding out of the scalene muscle below the skin (green arrow: internal jugular vein; red arrow: common carotid artery)

DISCUSSION

Migratory foreign body in the neck, although rare, has been well reported. In a review of 321 cases of penetrating foreign bodies only 43 of these cases were found to have migrated extraluminally into the neck soft tissues⁽¹⁾. A migrating foreign body can cause deep neck abscesses such as retropharyngeal or parapharyngeal abscess and complications to surrounding neurovascular structures depending on the route of migration. These are aorto-oesophageal fistula, innominate oesophageal fistula, subclavian oesophageal fistula, carotid rupture and brachial plexus injury which can have a serious or even fatal outcome⁽²⁾.

A complete history, physical examination and endoscopic evaluation are vital to arrive at the primary diagnosis of an ingested foreign body. Patients with an ingested foreign body commonly present with symptoms of choking, dysphagia, odynophagia or dysphonia. In some cases, these manifestations do not always correspond with the actual location of the foreign body; hence, it may be wise for the primary care doctor to have an index of suspicion on the possibility of a migrated foreign body. Fish bone can occasionally be found embedded in the palatine tonsils or base of tongue through inspection of the oropharynx using a tongue depressor and good light source. It can also be found impacted

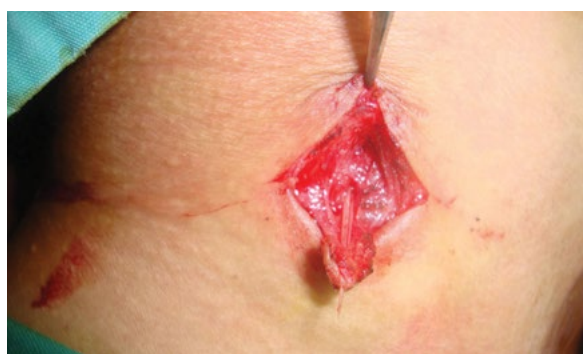

Fig. 3. Fish bone found embedded in the scalene muscle

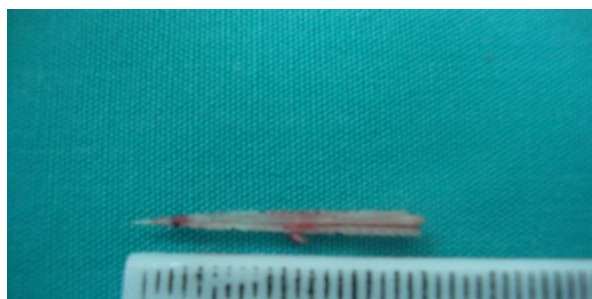

Fig. 4. A linear sharp fish bone measuring 20 mm

in the valleculae, the pyriform fossa or arytenoid cartilages by performing a flexible fiberoptic endoscopy⁽²⁾. Streaks of blood and oedema in the hypopharynx may be suggestive of migratory foreign body or trauma due to the spontaneous dislodgement of the foreign body. Pooling of saliva at the pyriform fossa is another important sign that the foreign body might be impacted lower down in the oesophagus.

Foreign body migration is suspected on the basis of suggestive history, a positive finding on lateral neck radiography, and a negative finding on flexible or rigid endoscopy⁽³⁾. In our case, the presenting complaints were pain and a projecting sharp foreign body below the skin over the right lateral neck, which, coupled with the history of recent consumption of fish bone and a full physical examination, and augmented by the negative laryngo-oesophagoscopy finding, alerted us to the possibility of migratory fish bone. There was no sign of subcutaneous emphysema, cellulitis or abscess, hence CT scan played an important role in confirming our suspicion and aided our surgical planning.

In a study by Hon et al., the great majority of patients with foreign bodies in the ear, nose and throat (66% to 94%) presented promptly within 24 hours to a primary care doctor. Likewise, following presentation to the first doctor, the great majority (80% to 94%) were referred to the otolaryngologist without any undue delay. In addition, very little delay occurred in the admission of the patients and in the removal of the foreign bodies. Further analysis of the results revealed that patients with aerodigestive tract foreign bodies tend to present earlier than those with ear or nose foreign bodies. 90% of patients with throat foreign bodies presented within 24 hours of ingestion of the foreign body, compared with 73% for ear and 63% for nose foreign bodies. In addition, 43% of the patients with aerodigestive tract foreign bodies presented within one hour of ingestion. These are not unexpected findings, as aerodigestive tract foreign bodies generally tend to cause more discomfort and inflict more pain on the patients than ear or nose foreign bodies⁽⁴⁾.

Plain lateral neck radiograph has a role in detecting a foreign body in the neck, is readily available in most hospitals and is less costly, although the sensitivity and specificity varies. In a study by Lue et al., the sensitivity and specificity of plain radiographs to detect the presence of fish bones were 39% and 72%, respectively⁽⁵⁾. CT scan plays a crucial role as a diagnostic tool in confirming the diagnosis of migratory

foreign body. It gives an estimated size of the foreign body besides its orientation and relationship to other vital structures in the neck. On the whole, it guides the surgeon during a neck exploration with its three-dimensional image of the foreign body⁽²⁾. Magnetic resonance imaging (MRI) has also proven effective in diagnosing non-metallic migrated foreign bodies missed by a prior CT scan, but is contraindicated in suspected metallic foreign body ingestion⁽³⁾.

Exploration of the neck via an external approach is usually the primary treatment choice for a migratory foreign body in the soft tissues of the neck, although an intraoral approach may occasionally be necessary. The position of the foreign body may change and it may not be in the same location as in the scans when the neck is extended during surgery. This is because of mobility of the soft tissues in relation to the bony and cartilaginous structures⁽⁶⁾. The use of intraoperative ultrasound is very helpful in identifying the location of a migrated foreign body in the neck and its relation to the surrounding blood vessels as well as in its removal⁽⁷⁾.

CONCLUSION

Migratory foreign bodies, although rare, are definitely associated with potentially serious outcomes if left untreated and ignored. A high index of suspicion, and early and appropriate intervention can help to avoid undesirable complications. CT scan of the neck plays an important role in diagnosing migratory foreign body in the neck and serves as a guiding tool for the surgeon during surgery. External exploration of the neck is the primary option of treatment in most cases of migratory foreign bodies in the neck.

Conflict of interest

The authors do not declare any financial or personal links to other persons or organisations that could adversely affect the content of this publication or claim rights thereto.

References

1. Remsen K, Lawson W, Biller HF et al.: Unusual presentations of penetrating foreign bodies of the upper aerodigestive tract. *Ann Otol Rhinol Laryngol Suppl* 1983; 105: 32–44.
2. Johari HH, Khaw BL, Yusof Z et al.: Migrating fish bone piercing the common carotid artery, thyroid gland and causing deep neck abscess. *World J Clin Cases* 2016; 4: 375–379.
3. Pai K, Pillai S, Bhandarkar A et al.: Migrating ingested foreign body of the upper aerodigestive tract with resultant septic shock: case report and literature review. *Sultan Qaboos Univ Med J* 2013; 13: 606–610.
4. Hon SK, Izam TM, Koay CB et al.: A prospective evaluation of foreign bodies presenting to the Ear, Nose and Throat Clinic, Hospital Kuala Lumpur. *Med J Malaysia* 2001; 56: 463–470.
5. Lue AJ, Fang WD, Manolidis S: Use of plain radiography and computed tomography to identify fish bone foreign bodies. *Otolaryngol Head Neck Surg* 2000; 123: 435–438.
6. Zohra T, Ikram M, Iqbal M et al.: Migrating foreign body in the thyroid gland, an unusual case. *J Ayub Med Coll Abbottabad* 2006; 18: 65–66.
7. Ng SY, Songra AK, Bradley PF: A new approach using intraoperative ultrasound imaging for the localization and removal of multiple foreign bodies in the neck. *Int J Oral Maxillofac Surg* 2003; 32: 433–436.