

A case of a syndromic preterm neonate in a “can ventilate, can’t intubate” condition: Guedel airway to the rescue!

Zastosowanie rurki Guedela u wcześniaka z zaburzeniami drożności górnych dróg oddechowych z powodu wrodzonej wady twarzoczaszki

Department of Otorhinolaryngology, Faculty of Medicine, Universiti Malaya, 50603 Kuala Lumpur, Wilayah Persekutuan Kuala Lumpur, Malaysia

Correspondence: Jeyasakthy Saniasiaya, Department of Otorhinolaryngology, Faculty of Medicine, Universiti Malaya, Jalan Universiti, 50603 Kuala Lumpur, Wilayah Persekutuan Kuala Lumpur, Malaysia, tel.: +6012-6841223, e-mail: shakthy_18@yahoo.com

ORCID iDs

1. Balinder Singh Deol <https://orcid.org/0000-0002-7265-0366>
2. Jeyasakthy Saniasiaya <https://orcid.org/0000-0003-1974-4379>
3. Jeyanthi Kulasegarah <https://orcid.org/0000-0001-8021-7864>

Abstract

Introduction: Upper airway distress associated with craniofacial anomaly has been reported widely. An antenatal scan of craniofacial anomaly should alert the attending team to prepare for respiratory distress in any neonate following delivery. Additionally, a stepwise algorithm is imperative to manage the difficult airway in children with craniofacial anomalies. **Aim:** To outline a case of difficult airway in a newborn with a craniofacial anomaly. **Case study:** A premature neonate, born at 36 weeks, was referred to the otorhinolaryngology team following the failure of intubation. Guedel oropharyngeal airway was inserted, and temporarily airway was managed with non-invasive ventilation. However, tracheostomy was subsequently performed, while the neonate was ventilated via face mask. **Discussion and conclusion:** Prompt management is of dire importance in handling a newborn with craniofacial anomaly in respiratory distress. Guedel oropharyngeal airway is a temporary measure used to secure the airway, while tracheostomy is performed.

Keywords: tracheostomy, Guedel airway, upper airway obstruction, neonatal airway management, difficult airway

Streszczenie

Wstęp: Zaburzenia czynności górnych dróg oddechowych związane z obecnością wad czaszkowo-twarzowych są stosunkowo często opisywane w literaturze. Każda wada czaszkowo-twarzowa uwidoczona w badaniach obrazowych w ramach diagnostyki prenatalnej powinna stanowić sygnał dla zespołu medycznego, aby przygotować się na wystąpienie zaburzeń oddychania po porodzie. W przypadku zaburzeń drożności dróg oddechowych u dzieci z wadami czaszkowo-twarzowymi konieczne jest stosowanie kilkietapowego algorytmu postępowania. **Cel pracy:** Przedstawienie przypadku zaburzeń drożności górnych dróg oddechowych u noworodka z wadą czaszkowo-twarzową. **Opis przypadku:** Wcześniak urodzony w 36. tygodniu ciąży został przekazany pod opiekę zespołu otorynolaryngologicznego po niepowodzeniu intubacji. Drożność dróg oddechowych zabezpieczono rurką ustno-gardłową Guedela i wdrożono nieinwazyjne wspomaganie oddechu. W późniejszym czasie u noworodka wykonano tracheostomię, jednocześnie prowadząc wentylację przez maskę twarzową. **Omówienie i wnioski:** W postępowaniu z noworodkami, u których na skutek wady czaszkowo-twarzowej rozwija się stan niewydolności oddechowej, liczy się odpowiednio wczesne podjęcie odpowiednich interwencji. Rurka ustno-gardłowa Guedela jest tymczasowym środkiem zabezpieczającym drożność dróg oddechowych do wykonywania tracheostomii.

Słowa kluczowe: tracheostomia, rurka ustno-gardłowa Guedela, niedrożność górnych dróg oddechowych, udrażnianie dróg oddechowych u noworodków, trudne drogi oddechowe

INTRODUCTION

Neonates are known to be obligate nasal breathers, although the recent literature points out that they may be “preferred nasal breathers”, as they can breathe through the mouth, yet may be unable to sustain effective breathing with concurrent nasal occlusion. Traditionally, the tongue of a neonate is relatively large compared to the overall oral cavity space, hence the presence of macroglossia in a child with micrognathia or retrognathia, which further narrow the airway space, may lead to respiratory distress. Additionally, the presence of cleft palate may result in the tongue obstructing both the oro- and nasopharynx simultaneously. Since craniofacial anomalies predispose children to airway obstruction, anticipation of early airway intervention is crucial, especially when the anomaly involves the midface and mandible (i.e. Pierre Robin, Apert, Treacher Collins, Saethre–Chotzen, CHARGE, Nager, Stickler, Goldenhar, and Pfeiffer). Additionally, a stepwise algorithm is imperative for managing the difficult airway in children. Recent cohort studies have reported that approximately 50–60% of infants below the age of 1 year underwent tracheostomies for upper airway obstruction due to craniofacial anomalies or structural airway abnormalities⁽¹⁾.

CASE STUDY

We report a case of a newly born baby boy with a birth weight of 1.78 kg who was delivered preterm at 36 weeks and 5 days via emergency caesarean section due to underlying foetal anomalies with polyhydramnios. Upon birth, the baby was not vigorous, not crying, with an Apgar score of 1 at 1 minute of life despite initial stimulation. Positive pressure ventilation (PPV) and cardiopulmonary resuscitation were commenced at birth, following a heart rate of less than 60 beats per minute and saturation at 30% under room air. Initial pressure gave 20/5 FiO₂ 100%, with the child not responsive to stimulation, apnoeic, and floppy. Cardiopulmonary resuscitation was performed for 1 minute and, subsequently, the heart rate picked up to 100 beats per minute. Oropharyngeal intubation was attempted by the paediatric medical team using a Miller laryngoscope (blade size 0) and an endotracheal tube size 3.0. However, it was unsuccessful, so PPV was continued with increased pressure of 26/6 FiO₂ 100%. The baby’s Apgar score at 5 minutes of life improved to 7. The child was clinically pink, the heart rate increased to more than 100 beats per minute despite eliciting facial grimace, with minimal flexion and slow irregular breathing. Subsequently, at 15 minutes of life, another unsuccessful attempt at intubation, using video laryngoscopy [CMAC (blade 0)] with an endotracheal tube size 3.0, was followed by the insertion of a Guedel airway size (0) and we managed to successfully ventilate the infant. The infant started having spontaneous breathing activity and was put on continuous positive air pressure (CPAP) ventilator with a positive end-expiratory pressure (PEEP) of 6 and FiO₂ of 100%.

We were able to maintain saturation above 95% with a heart rate of 120 bpm. Then the child was transferred to a neonatal intensive care unit (NICU), initially put on CPAP FiO₂ 30% PEEP6 with oxygen saturation of 100% and then changed to Optiflow FiO₂ 100% with a flow rate of 6 L/min. Nevertheless, the child developed respiratory acidosis with increasing carbon dioxide retention despite saturating above 92%. The NICU team then attempted nasopharyngeal airway intubation using an endotracheal tube size 3.0 and 2.5, but failed, so an ENT (ear, nose, and throat) team was called for the management of difficult airway.

After assessing the child and discussing the case with our paediatric neonatology colleagues, we counselled the parents of the infant who then consented to tracheostomy.

The child was then brought to the operating theatre for tracheostomy, which was performed at 5 hours of life using a size 3 mm non-cuffed tracheostomy tube. Intraoperatively, the infant had an episode of desaturation with hypotension and bradycardia during tracheal incision, and was successfully resuscitated by administering a 30 ml bolus of Hartmann’s solution, 1 dose of intravenous atropine, and 2 doses of intravenous adrenaline.

Post-tracheostomy airway assessment using flexible nasopharyngolaryngoscope showed that the right nasal cavity and choana were patent, however the left nasal cavity and choana were narrow. The epiglottis was visualised, but because of severe micrognathia causing glossoptosis and obstructing the airway, other laryngeal structures could not be visualised (Fig. 1). The scope was then passed via the tracheostomy, revealing that the trachea was clear as far as the carina. Oral cavity examination revealed no cleft lip or palate.

The infant was then nursed at the NICU and subsequently weaned off the ventilator on day 4 of life.

Upon thorough post-tracheostomy examination, the craniofacial anomaly was clearly seen (Fig. 2), including dysplastic ears, microtia, micrognathia, deep-seated eyes, low set ears, arthrogryposis over bilateral elbow (fixed flexion deformity), bilateral club foot, bilateral absent thumb, syndactyly over the right middle and ring finger. Other abnormalities includes subtle anterior beaking of the vertebral body, bilateral mild

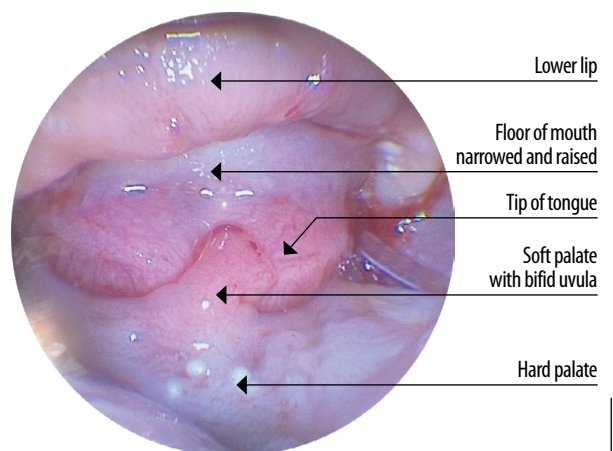


Fig. 1. Direct laryngoscopy findings

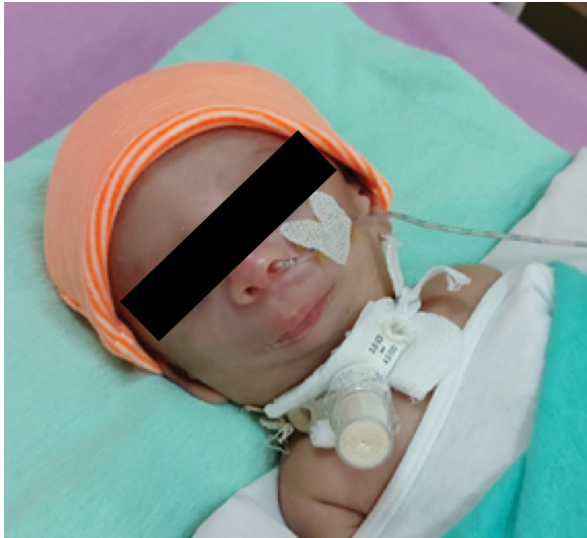

Fig. 2. Infant post tracheostomy

hydronephrosis of the kidney, left lung hypoplasia, and echocardiography findings of trivial tricuspid regurgitation with a peak pressure gradient of 18 mm Hg.

DISCUSSION

Neonates are known to be an extremely high-risk group with respect to difficult airway management. The occurrence of a truly difficult airway is rare but time-critical⁽²⁾. Difficult intubation is defined by the need for more than 2 attempts by a non-resident provider in a multicentre NICU. Therefore, preparation for difficult airway is of paramount importance in high-risk patients. A study reported by the National Emergency Airway Registry for Neonates (NEAR4NEOS) found that 14% (276 of 2,009) of intubations performed in the NICU met the definition of difficult intubation. Difficult intubations are more common in preterm neonates <32 weeks with a birth weight below 1,500 g⁽³⁾. An analysis of data in the Paediatric Difficult Intubation (PeDI) registry found that 20% of the patients meeting difficult tracheal intubation criteria had at least one complication. Consequently, attempting more than two tracheal intubations in children with difficult tracheal intubation is associated with a high failure rate and increased incidence of complications⁽⁴⁾. The Difficult Airway Society of the United Kingdom suggests that the attending team makes no more than two attempts with the same device before moving on to an alternative laryngoscopy device. The maximum number of laryngoscope attempts should be limited to 4. Paediatric difficult airway management can be divided into two categories: unanticipated and anticipated. The unanticipated difficult airway is rare and often caused by trauma, infection, or inexperienced airway practitioners. More commonly, the paediatric difficult airway can be anticipated. Significant changes in the airway anatomy due to genetic, embryologic, or surgical causes can complicate paediatric airway management⁽⁵⁾.

Preparation for the possibility of difficult airway should be undertaken in infants with craniofacial abnormalities including achondroplasia, Beckwith–Wiedemann syndrome, cleft palate, Goldenhar syndrome laryngeal cysts, Pierre Robin sequence, Treacher Collins syndrome, Down's syndrome, as well as children with cystic hygroma, and vascular malformations of the head and neck. Therefore, a multidisciplinary team discussion is important before birth if the diagnosis is suspected antenatally. In addition, a well-trained resuscitation team, consisting of neonatal consultants, paediatric ENT consultants, registrars, senior medical officers, and senior nurses, is required to be on standby and prepared.

Knowing which device is optimal based on the patient's specific airway anomaly can help prepare appropriately with suitable equipment. Ideally, the difficult airway pack including Guedel airways (size 00, 0, 1), laryngoscopes: handles, blades with appropriate sizes such as Miller straight blades (0, 00, 1) and curved Macintosh blades (size 0, 1)⁽⁶⁾ should be provided. Endotracheal tubes of appropriate sizes (sizes 2.0, 2.5, 3.0, 3.5), neonatal bougies, and supraglottic airway devices (size 0.5, 1) are essential. Other types of equipment that may aid in difficult intubation procedures are video laryngoscopes and fiberoptic bronchoscopes. Needle cricothyrotomy and surgical tracheostomy need to be considered in the intubate can't ventilate situation.

Our case reported here is an example of a "can't intubate can ventilate" scenario. Therefore, choosing an appropriate algorithm and reducing the number of intubation attempts limits trauma to the airway, converting it into a life-threatening "can't ventilate, can't intubate" scenario. If intubation is unsuccessful, inserting an laryngeal mask airway (LMA) should be considered as a rescue device and ventilation through the device should be provided. In this reported case, a Guedel airway, a type of oropharyngeal airway, was inserted into the infant's oral cavity, helping push the tongue away from obstructing the laryngeal inlet. In this way, we were able to ventilate the child.

Several devices are used for tracheal intubation, with laryngoscope being the primary method. Grading used during direct laryngoscopy evaluates the view of the larynx, which helps to anticipate a difficult airway. The view of the larynx is classified as follows:

- Grade 1 – visualisation of the entire laryngeal aperture, i.e. minimal difficulty with intubation.
- Grade 2 – visualisation of the posterior portion of the laryngeal aperture with some difficulty passing the ETT. The view can be improved by applying "cricoid pressure".
- Grade 3 – only the epiglottis can be visualised, which can result in severe difficulties. Cricoid/BURP (backward, upward, rightward pressure) may help with the visualisation.
- Grade 4 – the only visualisation is of the soft palate. Therefore, intubation is expected to be difficult.

If intubation is impossible, but the patient can be ventilated, the initial management should include a call for senior

help to optimise bag-mask ventilation, 2-person jaw thrust, Guedel or nasopharyngeal airway, suctioning the airway and decompressing the stomach. Subsequently, another attempt should be planned, using a different size laryngoscope blade, video laryngoscope (if available), LMA, and optimising the cricoid pressure or “BURP”, which stands for applying backwards, upwards, right pressure to the larynx and oesophagus to prevent aspiration, or by using a bougie; if this fails, the next option is to use fibre optic bronchoscopy and not hesitate to call an ENT specialist to consider a surgical airway, either needle cricothyroidotomy or tracheostomy.

Other intubation techniques, including awake fiberoptic intubation (FOI), have been the gold standard in managing the difficult airway in adults. However, the procedure is often impossible to perform in neonates and children due to poor cooperation. Therefore, it is recommended that spontaneous ventilation be maintained during the induction of anaesthesia and intubation, including inhalational anaesthetics or total intravenous anaesthetics. Ensuring an adequate depth of anaesthesia that prevents laryngospasm during airway manipulation, while maintaining spontaneous ventilation, requires advanced skills and practice. Two standard techniques to secure the airway include video laryngoscopes and FOI through a supraglottic airway (FOI-SGA). Video laryngoscopy has been shown to improve glottic visualisation; however, the technique may prolong the time needed for endotracheal tube insertion.

Supraglottic airway (SGA) vs. face mask

The goal of neonatal resuscitation is to provide positive pressure ventilation and maintain a patent airway, which is usually done using a face mask or an endotracheal tube. However, the disadvantage of a face mask is that an incorrect placement will lead to gas leakage around the rim. If too much pressure is applied, it may cause facial soft tissue injury, which typically requires a highly trained and skilled operator. The LMA provides advantages over the face mask; it does not require manipulating the patient’s head, neck, and jaw. It frees the operator’s hands after insertion, and has a better airtight seal. In addition, using a supraglottic airway as a conduit is useful for the administration of inhalational anaesthesia and continuous oxygenation and ventilation, avoiding hypoxemia in the most vulnerable paediatric population⁽⁶⁾.

A recent observational study based on data collected from the multicentre PeDI registry reported that, overall, first-attempt success rates were similar for children with a difficult airway undergoing video laryngoscopy and those undergoing FOI-SGA, and showed higher success rates with fewer incidents of hypoxia in children <1 year of age, supporting the recommendation for continued oxygenation during intubation⁽⁷⁾.

Bronchoscopy with flexible fibre optic remains the gold standard for managing the neonatal airway. The advantage over other devices is the aspiration of secretions.

The neonatal size has been introduced to improve the effectiveness of airway management. Using a flexible bronchoscope, inserting a 3 mm internal diameter can be passed, nasally and orally. Flexible bronchoscopy requires sedation of the newborn, especially with sevoflurane, which enables maintaining spontaneous ventilation. A special laryngeal mask with bronchoscope access may be used⁽⁸⁾.

LEARNING POINTS

Always have plans B, C, and D in place to handle the situation after plan A (intubation) has failed:

- choosing an appropriate algorithm is essential in each situation;
- limit the number of attempts of intubation to 2;
- where ventilation is adequate through bag-mask ventilation, and intubation is proving difficult, it is essential to remember that repeated intubation attempts can damage the airway and make bag-mask ventilation more difficult;
- appropriate preparation for high-risk infants with anticipated difficult airway is essential;
- there should be a very low threshold for referring these children for a specialist consultation in a tertiary unit;
- maintaining spontaneous ventilation in children with anticipated difficult airway is important;
- if all methods fail, the surgical airway is the next appropriate step.

Conflict of interest

The authors do not declare any financial or personal links to other persons or organisations that could adversely affect the content of this publication or claim rights thereto.

References

1. Chang J, Sidell DR: Tracheostomy in infants in the neonatal intensive care unit. *Neoreviews* 2020; 21: e323–e334.
2. Tinnion R, Fenton A: Managing the difficult neonatal airway: a BAPM framework for practice. *Infant* 2021; 17 (2): 56–59.
3. Sawyer T, Foglia EE, Ades A et al.: National Emergency Airway Registry for Neonates (NEAR4NEOS) investigators: Incidence, impact and indicators of difficult intubations in the neonatal intensive care unit: a report from the National Emergency Airway Registry for Neonates. *Arch Dis Child Fetal Neonatal Ed* 2019; 104: F461–F466.
4. Fiadjoe JE, Nishisaki A, Jagannathan N et al.: Airway management complications in children with difficult tracheal intubation from the Pediatric Difficult Intubation (PeDI) registry: a prospective cohort analysis. *Lancet Respir Med* 2016; 4: 37–48.
5. Park RS, Peyton JM, Kovatsis PG: Neonatal airway management. *Clin Perinatol* 2019; 46: 745–763.
6. Trevisanuto D, Micaglio M, Ferrarese P et al.: The laryngeal mask airway: potential applications in neonates. *Arch Dis Child Fetal Neonatal Ed* 2004; 89: F485–F489.
7. Dalesio NM: Planning Prevents Poor Performance: An Approach to Pediatric Airway Management. Available from: <https://www.apsf.org/article/planning-prevents-poor-performance-an-approach-to-pediatric-airway-management/>.
8. Hernández-Cortez E, Martínez-Bernal GF: Airway in the newborn patient. *J Anesth Crit Care Open Access* 2016; 5: 11–12.