

Mohd Farhan Afandi<sup>1</sup>, Jeyasakthy Saniasiaya<sup>1</sup>, Jeyanthi Kulasegarah<sup>1</sup>,  
Prepageran Narayanan<sup>2</sup>, Kein Seong Man<sup>2</sup>

Received: 26.10.2021  
Accepted: 20.06.2022  
Published: 31.03.2023

## Combined approach of transnasal and transoral endoscopic surgery in a child with nasal glial heterotopia

Przeznosowy i przezustny dostęp endoskopowy u dziecka z nosową heterotopią glejową

<sup>1</sup> Department of Otorhinolaryngology, Faculty of Medicine, Universiti Malaya, Malaysia

<sup>2</sup> Department of Pathology, Faculty of Medicine, Universiti Malaya, Malaysia

Correspondence: Jeyasakthy Saniasiaya, Department of Otorhinolaryngology, Faculty of Medicine, Universiti Malaya, Jalan Universiti, 50603 Kuala Lumpur, Wilayah Persekutuan Kuala Lumpur, Malaysia, tel.: +6012-6841223, e-mail: shakthy\_18@yahoo.com

### ORCID iDs

1. Jeyasakthy Saniasiaya <https://orcid.org/0000-0003-1974-4379>

2. Prepageran Narayanan <https://orcid.org/0000-0001-5670-9340>

### Abstract

**Aim of the study:** The aim of this case report is to outline the difficulties associated with managing a child with nasal glial heterotopia. Developmental midline nasal mass, especially of neurogenic origin, poses a great challenge to managing surgeons. Nasal glial heterotopia is among benign congenital midline nasal tumours with aggressive features. **Case report:** Herein, we report the case of a 5-month-old infant who presented earlier, at 3 months old, with respiratory distress secondary to obstructive nasal mass. **Result and discussion:** Imaging and bedside flexible nasopharyngolaryngoscopy showed a localised nasal mass with no intracranial tumour. Following two combined endoscopic intraoral and transnasal tumours, the diagnosis of nasal glial heterotopia was made, and the patient is under surveillance. **Conclusion:** Multidisciplinary team discussion along with combined endoscopic transnasal and transoral approach ought to be considered in managing challenging congenital nasal tumours in children.

**Keywords:** congenital tumour, benign tumour, nasal glial tumour, paediatrics, endoscopic surgery

### Streszczenie

**Cel pracy:** Celem opisu przypadku jest przedstawienie trudności związanych z leczeniem dziecka z nosową heterotopią glejową. Guz w obrębie nosa, umiejscowiony w linii pośrodkowej, zwłaszcza pochodzenia neurogennego, stanowi ogromne wyzwanie dla chirurgów. Nosowa heterotopia glejowa należy do wrodzonych, łagodnych guzów linii pośrodkowej o potencjalnie agresywnych cechach. **Opis przypadku:** W pracy przedstawiono przypadek 5-miesięcznego niemowlęcia, u którego uprzednio, w wieku 3 miesięcy, wystąpiły zaburzenia oddychania związane z obecnością guza powodującego obturację nosa. **Wyniki i omówienie:** Badania obrazowe oraz przyłóżkowa ocena za pomocą giętkiego nasofaryngolaryngoskopu wykazały obecność miejscowej masy guzowej bez towarzyszącego guza wewnątrzczaszkowego. Na podstawie wyniku badania endoskopowego z dojścia przezustnego i przeznosowego ustalono rozpoznanie nosowej heterotopii glejowej. Pacjenta objęto obserwacją. **Wnioski:** Leczenie trudnych guzów wrodzonych umiejscowionych w obrębie nosa u dzieci wymaga zaangażowania zespołu wielodyscyplinarnego. Przy procedurach endoskopowych należy brać pod uwagę dostęp przeznosowy i przezustny.

**Słowa kluczowe:** guz wrodzony, guz łagodny, guz glejowy w obrębie nosa, pediatria, chirurgia endoskopowa

## INTRODUCTION

**N**asal neuroglial heterotopia (NGH), or nasal glioma, is a developmental midline mass of neurogenic origin characterised by the presence of dysplastic non-teratomatous extracranial glial tissue losing its intracranial communication<sup>(1)</sup>. The incidence of congenital nasal masses has been reported as 1 per 20,000 to 40,000 live births<sup>(2)</sup>. Reid first described the nasal glioma in 1892, whereas Schmidt was the first to present a comprehensive description of this entity and coined the term glioma in 1900. The term “glioma” is in fact a misnomer, as it is not a true neoplasm. In infants presenting with nasal mass and respiratory distress, nasal glioma must be considered as one of the differential diagnoses<sup>(3)</sup>. This case report aims to highlight the challenges involved in managing nasal glial heterotopia in a child with cleft palate, and discuss the combined transnasal and transoral excision approach, keeping in mind the possibility of disease recurrence.

## CASE REPORT

A 5-month-old baby boy with cleft palate, born at term via spontaneous vaginal delivery, was referred for the management of a congenital intranasal mass. According to the baby’s parents, they noticed noisy breathing when the child was 3 months old. The noisy breathing was not associated with choking, cyanosis or respiratory distress, and it did not improve with positioning or crying. The boy was able to tolerate breastfeeding well. However, the child developed

respiratory distress, and an emergency tracheostomy was performed successfully to secure the airway.

Upon examination, the child was comfortable, with a single-lumen tracheostomy size 3.5. Bedside flexible nasopharyngolaryngoscopy revealed a fleshy intranasal mass with an oropharyngeal extension. The supraglottic structures were normal, and the vocal cords were bilaterally mobile. Magnetic resonance imaging (MRI) revealed a minimally enhancing mass in the left lateral nasopharyngeal and oropharyngeal region, with soft palate involvement. The mass has no communication with the brain. Examination under anaesthesia and biopsy of the intranasal mass revealed the presence of glial tissue and respiratory cells (Fig. 1) positive for glial fibrillary acidic protein (GFAP) (Fig. 2), which supported the diagnosis of nasal glial heterotopia.

After a multidisciplinary team meeting, the child underwent an endoscopic transnasal and transoral excision of the nasal mass under general anaesthesia. Intraoperatively, a smooth mass arising from the left side of the posterior part of the soft palate and left lateral nasopharyngeal wall with the uvula displaced to the right-soft palate cleft was excised in toto. Posterior septectomy was performed to access the mass. Postoperatively, the child was well and was discharged home after two days.

On subsequent follow-up, the child was well, and the developmental milestones were appropriate for age. However, a surveillance MRI done six months postoperatively showed a residual mass over the left lateral nasopharynx, with soft palate involvement. Endoscopically, the residual mass was smooth-surfaced and visible at the lateral nasopharynx (Fig. 3).

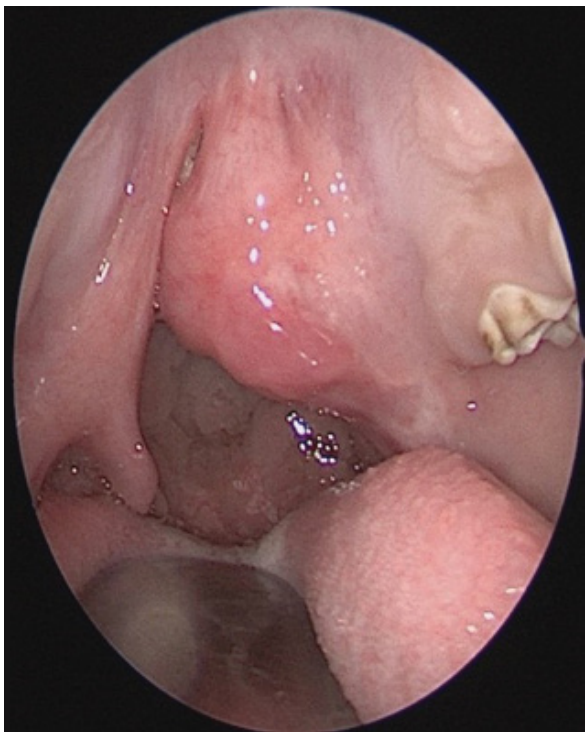


Fig. 1. Residual mass at lateral nasopharynx

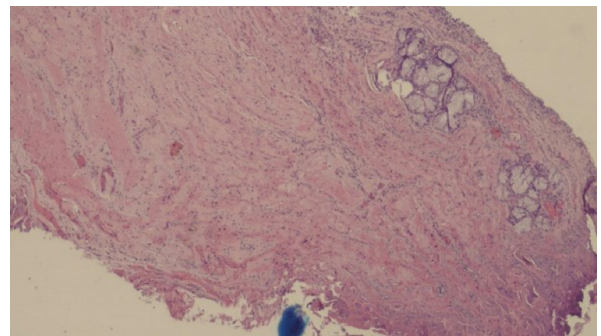


Fig. 2. Glial tissue with respiratory cells

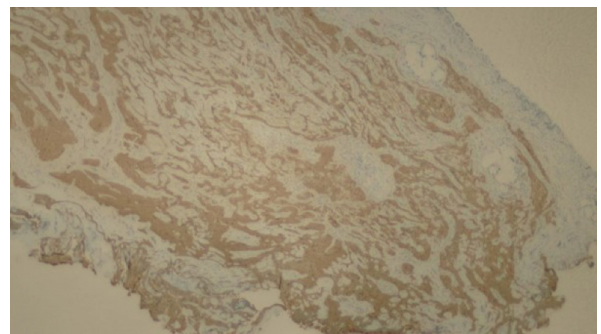


Fig. 3. Glial tissue positive for GFAP

The child was carefully evaluated and planned for revision surgery which was done at 2 years of age, with a successful outcome. Currently, the child is under regular follow-up.

## DISCUSSION

NGH accounts for 5% of all congenital nasal masses<sup>(4)</sup>. It is believed to originate from the entrapment of the neuroectodermal tissue during the closure of the tissue that covers the brain or from a nasal encephalocele that becomes covered by the dura, pia, and arachnoid meninges and is sequestered from the intracranial cavity during subsequent embryonic development<sup>(5)</sup>. NGH has been reported to be found extranasally in 60% of cases, followed by 30% intranasally, with the remaining 10% found on both sides. Extracranial involvement of NGH is regarded as non-neoplastic glial heterotopia<sup>(6)</sup>. The pathogenesis of glial heterotopia entails two mechanisms: one involves a primary bony defect of the skull base that might be due to the failure of ossification and chondrification, and the other is associated with the failure of the anterior neuropore, which closes by the end of the fourth gestational week. Consequently, if there is a partial or complete closure of the bony defect, the encephalocele will be sequestered and turn into neuroglial heterotopia<sup>(7)</sup>.

A review of the literature shows that NGH is commonly encountered during the first year of life, although there are also a few reported cases involving adult patients<sup>(8)</sup>. Male predominance has been reported. In a case series consisting of 21 NGH cases reported by Aidil et al., the male to female ratio of 2:1 was noted.

Children with intranasal masses commonly present with symptoms mimicking rhinitis, such as nasal obstruction and rhinorrhoea<sup>(9)</sup>. However, respiratory distress may also be the first presentation in a small number of patients, especially in infants, as they are obligate nasal breathers<sup>(9)</sup>. Extranasal tumours, on the other hand, present with a mass on the bridge or dorsum of the nose.

It is noteworthy that a routine evaluation of the airway by means of flexible fiberoptic nasopharyngoscopy is advisable to assess the upper airway. Any mass occupying the nasopharynx might cause significant obstruction of the upper airway especially during the early months of life.

As for the recommended diagnostic modalities, imaging in the form of MRI is superior in terms of evaluating the nature, location, extension and, most importantly, determining the intracranial extension of the mass. MRI alone is adequate to evaluate NGH without intracranial extension, as suggested by Adil et al.<sup>(9)</sup>. High resolution computed tomography can also provide detail of the bony anatomy of the skull base and help look for possible anatomical bony defects. Preoperative biopsy and resection are risky without proper imaging, as the presence of a connection with the central nervous system may lead to devastating complications including cerebrospinal fluid leakage, meningitis or even encephalocele<sup>(4)</sup>. In the same vein, routine

postoperative imaging is imperative to look for the possibility of recurrence. The recurrence rate has been reported to be approximately 4–10%<sup>(10)</sup>. Neuroimaging also helps to distinguish NGH from other lesions such as meningoencephalocele, dermoid cyst, glioma, and craniopharyngioma. Meningoencephaloceles commonly have direct communication through a skull base defect with the cranial vault and exhibit a hypointense signal on T1-weighted and FLAIR images, similarly to brain tissue<sup>(11)</sup>. The most common location of skull base meningoencephaloceles is frontoethmoidal (80%)<sup>(11)</sup>. Heterotopic neuroglial tissue may be located within or, most commonly, outside the cranial vault. It is most frequently found in the nasal cavity, but it has also been reported in the orbit, pterygopalatine fossa, middle ear, neck, thorax, and pharynx<sup>(12)</sup>. The typical neuroimaging appearance of heterotopic neuroglial tissue involves intermingled T1 and T2 signal characteristics of brain grey and white matter, with small enclosed cysts. Hypointense signal on T1-weighted images usually differentiates nasal gliomas from oropharyngeal dermoid cysts.

Tissue diagnosis in NGH is always challenging, for it is often impossible to differentiate NGH from encephaloceles, with glial tissue being predominantly present across the spectrum of both lesions<sup>(13)</sup>. Yeoh et al. compared 22 cerebral heterotopias with 11 encephaloceles and found no histologic differences between the two entities<sup>(14)</sup>. Hence, the difference between encephaloceles and neuroglial heterotopias is made based on imaging findings, whereby encephaloceles are found to maintain communication to the intracranial space. Histologically, the glial elements are often difficult to identify, especially with the presence of inflammatory components such as lymphocytes<sup>(15)</sup>. In our case, special immunohistochemistry staining was done, using S100 and GFAP, which is inconsistent with the findings reported by Buckner et al.<sup>(16)</sup>.

Surgical resection remains the definitive management for NGH to date, whereby complete surgical excision is recommended to reduce the chance of recurrence. Although the mass is benign and slow-growing, signs of airway compromise and feeding difficulty warrant an early intervention. Additionally, a delay in surgical resection adversely affects craniofacial growth. Recent advancements in endoscopic technique have revolutionised surgical resection, enabling complete resection, reducing morbidity and accelerating healing<sup>(17)</sup>. Endoscopy permits a clear view of each wall of the nasal cavity, supporting precise excision of intranasal glioma with minimal damage to the surrounding normal tissue. Parallel to that, angled endoscopy allows visualisation of the intricate location of the tumour to aid in complete tumour resection<sup>(18)</sup>. 25% of NGHs have been reported to have an association to the skull base via a fibrous stalk, which was not present in our case. Hu et al. reported a case of parapharyngeal glial heterotopia whereby an endoscopic transoral approach was combined with stereotactic navigation and intraoperative Doppler ultrasound to effectively map the tumour and its relation to the internal

carotid artery<sup>(17)</sup>. Regular follow-up with repeated scans is advisable due to the possibility of recurrence of the condition, especially in cases where only incomplete resection is achievable.

## CONCLUSION

Albeit benign and slow-growing, NGH may lead to significant airway compromise, which warrants an early intervention. Careful clinical assessment, as well as radioimaging, are recommended before embarking on any procedure. Needle aspiration is to be avoided due to the risk of cerebral spinal fluid leak and meningitis. The specific management depends on the correlation of histopathological findings and imaging. In the hands of an experienced surgeon, an endoscopic approach is usually sufficient to achieve a complete resection of the intranasal mass.

### Conflict of interest

*The authors do not declare any financial or personal links to other persons or organisations that could adversely affect the content of this publication or claim rights thereto.*

### References

1. Verney Y, Zanolli G, Teixeira R et al.: Midline nasal mass in infancy: a nasal glioma case report. *Eur J Pediatr Surg* 2001; 11: 324–327.
2. Haloob N, Pepper C, Hartley B: A series of parapharyngeal glial heterotopia mimicking lymphatic malformation. *Int J Pediatr Otorhinolaryngol* 2015; 79: 1975–1979.
3. Van Wyhe RD, Chamata ES, Hollier LH: Midline craniofacial masses in children. *Semin Plast Surg* 2016; 30: 176–180.
4. Bradley PJ, Singh SD: Congenital nasal masses: diagnosis and management. *Clin Otolaryngol Allied Sci* 1982; 7: 87–97.
5. Hedlund G: Congenital frontonasal masses: developmental anatomy, malformations, and MR imaging. *Pediatr Radiol* 2006; 36: 647–662.
6. Jaffe BF: Classification and management of anomalies of the nose. *Otolaryngol Clin North Am* 1981; 14: 989–1004.
7. Clarós P, Bandos R, Clarós A Jr et al.: Nasal gliomas: main features, management and report of five cases. *Int J Pediatr Otorhinolaryngol* 1998; 46: 15–20.
8. Hagiwara A, Nagai N, Ogawa Y et al.: A case of nasal glial heterotopia in an adult. *Case Rep Otolaryngol* 2014; 2014: 354672.
9. Adil E, Robson C, Perez-Atayde A et al.: Congenital nasal neuroglial heterotopia and encephaloceles: an update on current evaluation and management. *Laryngoscope* 2016; 126: 2161–2167.
10. Yan YY, Zhou ZY, Bi J et al.: Nasal glial heterotopia in children: two case reports and literature review. *Int J Pediatr Otorhinolaryngol* 2020; 129: 109728.
11. Wagner MW, Haileselassie B, Kannan S et al.: Oropharyngeal dermoid cyst in an infant with intermittent airway obstruction. A case report. *Neuroradiol J* 2014; 27: 627–631.
12. Huisman TAGM, Brehmer U, Zeilinger G et al.: Parapharyngeal neuroglial heterotopia extending through the skull base in a neonate with airway obstruction. *J Pediatr Surg* 2007; 42: 1764–1767.
13. Rahbar R, Resto VA, Robson CD et al.: Nasal glioma and encephalocele: diagnosis and management. *Laryngoscope* 2003; 113: 2069–2077.
14. Yeoh GP, Bale PM, de Silva M: Nasal cerebral heterotopia: the so-called nasal glioma or sequestered encephalocele and its variants. *Pediatr Pathol* 1989; 9: 531–549.
15. Charrier JB, Leboulanger N, Roger G et al.: [Nasal glial heterotopia: embryological and clinical approaches]. *Rev Stomatol Chir Maxillofac* 2006; 107: 44–49.
16. Buckner JC, Brown PD, O'Neill BP et al.: Central nervous system tumors. *Mayo Clin Proc* 2007; 82: 1271–1286.
17. Hu J, Ta J, Deisch J et al.: Image-guided transoral resection of recurrent parapharyngeal space glial heterotopia. *Int J Pediatr Otorhinolaryngol* 2014; 78: 366–369.
18. Yokoyama M, Inouye N, Mizuno F: Endoscopic management of nasal glioma in infancy. *Int J Pediatr Otorhinolaryngol* 1999; 51: 51–54.