

Fedir Yurochko¹, Dzenyaslava Kopanska¹, Oleksandra Bonetska², Mykola Bihun³

Pfeiffer syndrome – a case report

Zespół Pfeiffera – opis przypadku

¹ Department of Paediatric Otorhinolaryngology, Lviv Regional Paediatric Clinical Hospital OHMATDYT, Lviv, Ukraine

² Department of Pathology of the Premature Newborn Babies, Lviv Regional Clinical Hospital, Lviv, Ukraine

³ Department of Radiology, LLC EUROCLINIC, Lviv, Ukraine

Correspondence: Fedir Yurochko, Department of Paediatric Otorhinolaryngology, Lviv Regional Paediatric Clinical Hospital OHMATDYT, Lysenka Street 31, 79000 Lviv, Ukraine, tel.: +380974812521, e-mail: fyuroch@yahoo.com

Abstract

Pfeiffer syndrome is a severe autosomal dominant condition that affects many systems of the human body. It is caused by mutations in the fibroblast growth factor receptors of the fibroblast growth factor genes. The phenotype of patients with Pfeiffer syndrome includes multiple limb and cranial abnormalities, and mental retardation. The infant reported here also had cloverleaf-shaped skull, broad thumbs and big toes, bilateral syndactyly, and hypertelorism. The patient was hospitalised in the Lviv Regional Clinical Hospital with multiple congenital malformations and severe neurological status. Acrocephaly, cloverleaf-shaped skull and severe concomitant neurological complications suggested Pfeiffer syndrome, which was later confirmed.

Keywords: Pfeiffer syndrome, cloverleaf-shaped skull, craniosynostosis, hypertelorism

Streszczenie

Zespół Pfeiffera jest ciężką chorobą dziedziczną w sposób autosomalny dominujący, która wpływa na wiele układów organizmu człowieka. Schorzenie jest wywołane mutacjami w genach kodujących receptory czynnika wzrostu fibroblastów. Fenotyp pacjentów z zespołem Pfeiffera obejmuje liczne nieprawidłowości w obrębie kończyn i czaszki oraz opóźnienie rozwoju umysłowego. U opisanego w pracy niemowlęcia stwierdzono ponadto czaszkę typu trójlistnej koniczyny, szerokie kciuki i paluchy, obustronną syndaktylię oraz hiperteloryzm. Pacjent był hospitalizowany we Lwowskim Obwodowym Szpitalu Klinicznym z powodu licznych wad wrodzonych, w ciężkim stanie neurologicznym. Akrocefalia i czaszka w kształcie trójlistnej koniczyny oraz ciężkie współistniejące powikłania neurologiczne wskazywały na zespół Pfeiffera – rozpoznanie to zostało później potwierdzone.

Słowa kluczowe: zespół Pfeiffera, czaszka typu trójlistnej koniczyny, kraniosynostoza, hiperteloryzm

INTRODUCTION

Pfeiffer syndrome is a rare autosomal dominant genetic disorder characterised by suture craniosynostosis leading to cranial abnormalities (acrocephaly and midfacial hypoplasia) and multiple limb defects (broad and big toes, less often syndactyly). In addition, such patients exhibit intellectual disability, congenital anomalies of the nervous system, malformations of ENT-organs (ear, nose, and throat), and the visual organ.

CLINICAL CASE

Our own report of a patient with Pfeiffer syndrome is provided below.

The boy I., aged 6 hours, was admitted to the Department of Preterm Neonate Pathology of the Lviv Regional Clinical Hospital with multiple congenital malformations and in a severe neurological condition.

Based on extracts from the case history, the boy was born to a G1P1 mother with a risk for miscarriage at 16–17 weeks. Upon the ultrasonographic examination at 28 weeks, a congenital central nervous system (CNS) anomaly – Arnold–Chiari malformation – was suspected. Except for CNS anomalies, no other abnormalities in foetal development were detected. The child was delivered vaginally at 37 weeks of gestation. The Apgar score was 6/6 points. The birth weight was 3,100 g, body length – 54 cm, head circumference – 32 cm.

At the time of admission, the child's condition was grave. The body structure was irregular, with multiple malformations including acrocephaly, craniofacial dysmorphism (buphthalmos, vertical nystagmus, hypertelorism, broad nasal bridge, maxillary hypoplasia, progenesis, high-arched palate, low-set ears) (Figs. 1, 2). The thumbs and big toes were broad, while other fingers and toes are wedge-shaped. Skin: clear, pale, subicteric with perioral cyanosis and acrocyanosis.

Respiratory system: irregular breathing; no nasal breathing, breathing through the mouth, respiratory rate 50/min. Auscultation revealed suppressed breath sounds over the lungs. Cardiovascular system: cardiac borders within normal range, heart rate 90/min. Rhythmical, muffled heart tones. Weak femoral pulse. Digestive system: swollen abdomen; liver – +4 cm, spleen along the costal margin. Nervous system: sluggish response to the examination, no crying, weak movements. Mild limb tremor. Sluggish pupillary light reflex. Weak muscle tone. Suppressed reflexes. Osteoarticular system: deformed skull, cloverleaf-shaped. Reproductive system: male type, right testicle enlarged. No abnormalities in laboratory blood and urine parameters. Ultrasonography of the abdominal organs: suspected pyloric stenosis. Echocardiography: patent ductus arteriosus at the stage of closure, heart chambers not dilated, normal structure and function of the heart valves. Satisfactory myocardial contractility.

Cranial computed tomography (CT) performed at the age of 3 weeks (Figs. 3–5): multiple malformations, cloverleaf-shaped skull, craniostenosis, exophthalmos. The skull is prolate at the level of frontoparietal bones, and expanded transversely at the level of the temporal bones; the occipital bone is flattened. The brain is deformed, reflecting skull deformities, with prominent ventriculomegaly and compression of metencephalon structures. The nasal cavity is asymmetrical, with significantly narrowed nasal passages. The position of the sphenoid bone is low and atypical. The nasal septum grows backwards, dividing the nasopharyngeal cavity into two halves (Fig. 5). Small orbital fissures, bilateral proptosis, and wide-spaced eyeballs.

Genetic consultation: craniofacial dysostosis, suspected Pfeiffer syndrome. At this point, the results of genetic testing to confirm the syndrome are expected. Otolaryngology consultation: choanal stenosis, nasal septum deviation. Ophthalmology consultation: multiple congenital malformations of the visual analyser: buphthalmos, megalocornea, keratoectopia, disc hypoplasia. Neurologist consultation: suppression syndrome. Newborn hearing screening ABR (auditory brainstem response): failed in both ears.

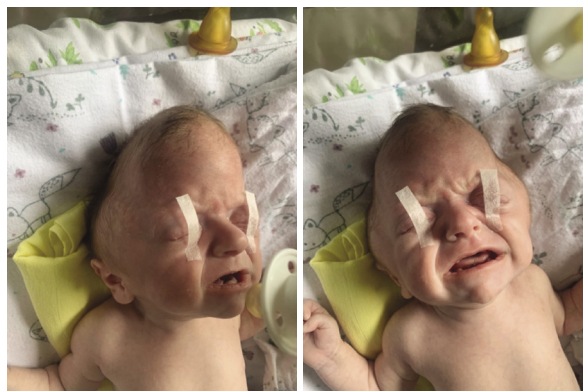Currently, the child is under the supervision of his attending doctors (Fig. 6), and further surgical corrections of congenital malformations are planned. The surgical removal of inguinal hernia has already been performed, with good tolerance of the procedure. The post-surgical period appeared unremarkable. The next surgical intervention should be neurosurgical treatment to separate synostosed sutures. The patient has a significant psychomotor impairment.

DISCUSSION

Pfeiffer syndrome is a very rare genetic disorder. It was first described by Rudolf Pfeiffer in 1964⁽¹⁾. The incidence of Pfeiffer syndrome is 1/100,000 births⁽²⁾.

The classification of Pfeiffer syndrome is crucial for correct diagnosis and prognosis. There are three types of this syndrome.

Type 1 (classic) is characterised by moderately mild manifestations. Affected patients have normal intelligence, and



Figs. 1, 2. Patient with Pfeiffer syndrome at birth

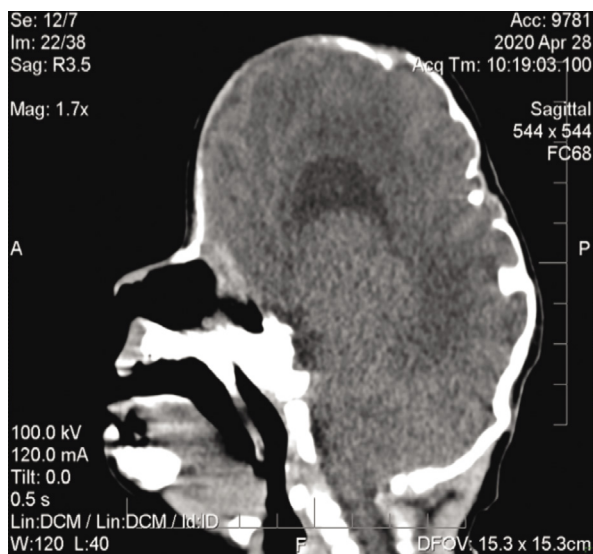


Fig. 3. Head CT scan (sagittal midline section)

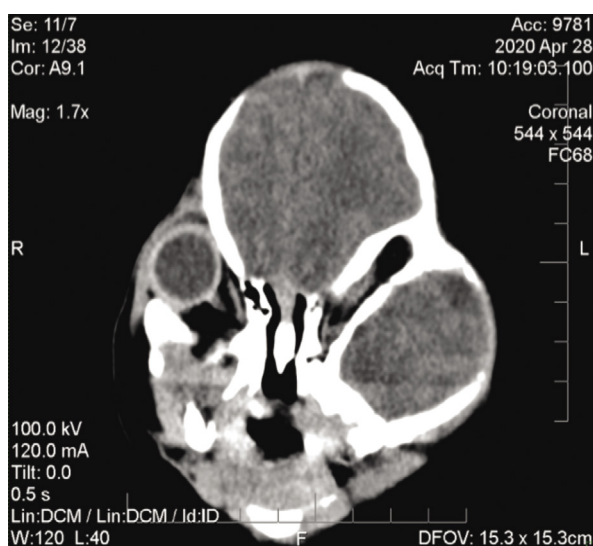


Fig. 4. Head CT scan (coronal section)

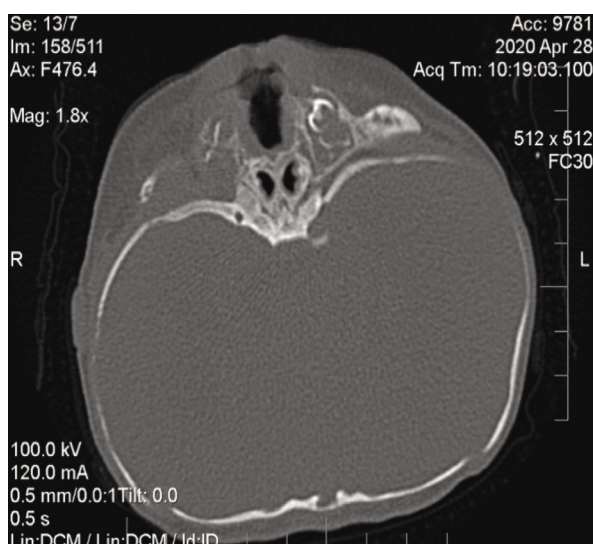


Fig. 5. Head CT scan (axial section at the level of the nasopharynx)

the outcome is generally good. This type consists of finger and toe malformations, hypocalvaria, and brachycephaly. Type 2 involves “Pfeiffer hands and feet,” i.e. the thumbs and big toes are very broad and deviated radially; and the soft tissues between the second, third and fourth digits of either or both hands and feet are often fused to the proximal portions of distal phalanges. These patients also have ankylosis or synostosis of elbow joints, a cloverleaf-shaped skull, severe mental disability, and severe concomitant neurological complications.

Patients with Pfeiffer syndrome type 3 often are affected by multiple visceral malformations. The type is characterised by proptotic eyes and a noticeably short anterior skull base. The manifestations are very similar to type 2. The main and only difference is the absence of a cloverleaf-shaped skull. Pathogenetically, Pfeiffer syndrome is caused by mutations in the fibroblast growth factor receptor gene – *FGFR* gene. Mutations in this gene also cause Apert syndrome, Crouzon syndrome, and other syndromes associated with craniosynostosis and various facial defects.

Pfeiffer syndrome type 1 is associated with the *FGFR1* gene (5%) on chromosome 8’s short arm, and the *FGFR2* gene (95%). Types 2 and 3 are associated only with the *FGFR2* gene (100%) on the long arm of chromosome 10. The mutations occur in exons IIIa and IIIc⁽³⁾. Exon mutations in the genes encoding cell membrane protein cause impairment of cellular differentiation and, consequently, lead to multiple malformations.

The clinical implications of Pfeiffer syndrome include primarily midface malformations, and anomalies of the limbs and visual organ.

Patients have a cloverleaf-shaped skull. The pathogenesis of this deformity remains unknown. However, facial malformations and hydrocephalus occur due to intrauterine craniosynostosis. After birth, the internal dimensions of the skull are very small. As a result, patients have increased intracranial pressure manifested through severe head pain. An interesting CT feature in the reported patient is the low position of the sphenoid bone and a nasal septum dividing the nasopharynx into two halves.

Ophthalmic pathology is another intrinsic feature of the syndrome. It is manifested in various ways: Peter’s anomaly – anterior segment dysgenesis and corneal opacity, hypertelorism, strabismus, low-spaced eye slits, optic nerve atrophy⁽⁴⁾. Progressive changes in the optic nerve, its oedema and atrophy can occur even in the absence of hydrocephalus. Due to the underdeveloped maxillary bone, patients with Pfeiffer syndrome have very small orbits with severe proptosis often causing endophthalmitis and corneal ulcers. Maxillary hypoplasia leads to anatomical changes in the larynx and pharynx, restricting the flow of air to the trachea and lungs, and, consequently, causing respiratory disorders. Regurgitation, i.e. problems with gastric transit, may also occur⁽⁵⁾.

The shape of the limbs is a pathognomonic symptom of Pfeiffer syndrome. The distal phalanges are fused, while the thumbs and big toes are very broad and deviated radially.

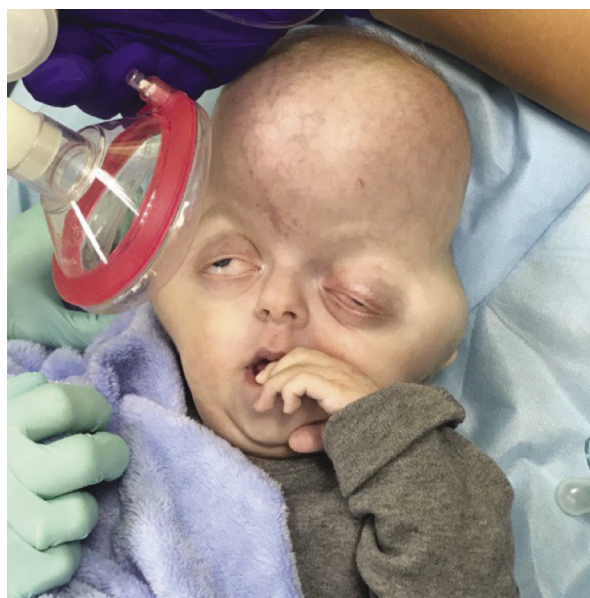

Fig. 6. Patient with Pfeiffer syndrome at the age of 6 months

Other malformations occurring in children with Pfeiffer syndrome include recurrent otitis media, choanal atresia, cleft palate, tracheo- and bronchomalacia, as well as Arnold-Chiari malformation⁽⁶⁾.

The primary treatment involves surgical correction. The general treatment plan for patients with Pfeiffer syndrome involves staged surgeries. The surgical correction is extensive and quite complex.

In the first year of life, it is mandatory to separate the synostosed sutures to ensure the normal volume of the skull and, thus, normal brain growth and expansion. The surgeries typically include ventriculostomy (or shunt implantation) to reduce increased intracranial pressure, as well as posterior skull reconstruction. Neurosurgical treatment is repeated at the age of 2–3 years.

A very important part of treatment is orbital volume expansion and lateral orbital expansion to allow the eyeballs to sink back and the eyelids to close. Finger and toe anomalies do not usually require any significant surgical correction.

The prognosis for patients with Pfeiffer syndrome is often poor, especially for types 2 and 3. Due to severe concomitant congenital malformations, they tend to die early.

CONCLUSIONS

Genetic disorders were a mystery for a long time. However, their aetiology and pathogenesis are being extensively researched nowadays. Pfeiffer syndrome is one of the rare disorders which are actively studied all over the world. Our case report of a patient with Pfeiffer syndrome is consistent with the available literature. The main manifestations of the syndrome include an abnormal cloverleaf-shaped skull, buphthalmos, megalocornea, and limb defects in the form of fused and broad phalanges. Our patient is currently under medical supervision and needs further staged surgical corrections.

Conflict of interest

The authors do not report any financial or personal connections with other persons or organisations which might negatively affect the content of this publication and/or claim authorship rights to this publication.

References

1. Pfeiffer RA: [Dominant hereditary acrocephalosyndactylia]. *Z Kinderheilkd* 1964; 90: 301–320.
2. Park MS, Yoo JE, Chung J et al.: A case of Pfeiffer syndrome. *J Korean Med Sci* 2006; 21: 374–378.
3. Schell U, Hehr A, Feldman GJ et al.: Mutations in *FGFR1* and *FGFR2* cause familial and sporadic Pfeiffer syndrome. *Hum Mol Genet* 1995; 4: 323–328.
4. Chen CP, Huang HK, Liu YP et al.: Pfeiffer syndrome with *FGFR2* W290C mutation perinatally presenting extreme proptosis. *Taiwan J Obstet Gynecol* 2013; 52: 607–610.
5. Freeman L, Elakis G, Watson G et al.: Pfeiffer syndrome with neonatal death secondary to tracheal obstruction owing to the *FGFR2* Glu565Ala mutation. *Clin Dysmorphol* 2008; 17: 223–224.
6. Giancotti A, D'Ambrosio V, Marchionni E et al.; PECRAM Study Group: Pfeiffer syndrome: literature review of prenatal sonographic findings and genetic diagnosis. *J Matern Fetal Neonatal Med* 2017; 30: 2225–2231.