

Hubert Paweł Szyller, Martyna Wrześniewska, Julia Wołoszczak,
Joanna Braksator, Tomasz Pytrus

Received: 04.12.2023

Accepted: 24.04.2024

Published: 27.09.2024


Autoimmune hepatitis – an increasingly common cause of hypertransaminasaemia among children.

Case report and literature review

Autoimmunologiczne zapalenie wątroby – coraz częściej spotykana przyczyna hipertransaminazemii u dzieci. Opis przypadku i przegląd literatury

2nd Clinical Department of Paediatrics, Gastroenterology and Nutrition, Wrocław Medical University, Wrocław, Poland

Correspondence: Hubert Paweł Szyller, 2nd Clinical Department of Paediatrics, Gastroenterology and Nutrition, Wrocław Medical University, M. Curie-Skłodowskiej 50/52, 50-369 Wrocław, Poland, e-mail: hermeszyller@gmail.com

 <https://doi.org/10.15557/PiMR.2024.0021>

ORCID iDs

1. Hubert Paweł Szyller <https://orcid.org/0000-0003-4781-4151>
2. Martyna Wrześniewska <https://orcid.org/0009-0007-7710-3680>
3. Joanna Braksator <https://orcid.org/0000-0003-0071-2959>
4. Tomasz Pytrus <https://orcid.org/0000-0001-7609-8479>

Abstract

Autoimmune hepatitis is a chronic inflammatory process of unknown ethology, characterised by high levels of transaminases and IgG antibodies, the presence of tissue autoantibodies, and a typical histological picture. In the population of children, the paediatric form of autoimmune hepatitis and autoimmune sclerosing cholangitis are collectively classified as juvenile autoimmune liver disease. The condition often coexists with other autoimmune disorders. This paper aims to present the clinical profile of a paediatric patient with full-blown autoimmune hepatitis and describe the available therapies. The patient, a 13-year-old boy, was referred to a specialised hospital because of increasing hypertransaminasaemia. The patient was hospitalised for the first time at a district hospital for abdominal pain, and during his stay, elevated transaminases were found with a tendency to increase in follow-up tests. The picture suggested an inflammatory process of the liver and biliary tract. Upper gastrointestinal endoscopy revealed lesions consistent with chronic gastritis and portal gastropathy. Treatment included thiazolidinedioic acid, vitamin K, ursodeoxycholic acid, rifaximin, ciprofloxacin, and proton pump inhibitors. Therapy is aimed at maintaining immunosuppression and inhibiting the inflammatory response that leads to cirrhosis, and most commonly uses steroids alongside proton pump inhibitors for added protection or, alternatively, mycophenolate mofetil, cyclosporine A, tacrolimus, and biologic therapy. Ursodeoxycholic acid also exhibits immunomodulatory properties and makes it possible to reduce steroid doses and thus decrease the likelihood of adverse effects of therapy.

Keywords: paediatrics, autoantibodies, autoimmune hepatitis, hypergammaglobulinaemia

Streszczenie

Autoimmunologiczne zapalenie wątroby jest przewlekłym procesem zapalnym o nieznannej etiologii, charakteryzującym się wysoką aktywnością transaminaz i wysokim mianem przeciwciał IgG, obecnością autoprzeciwciał tkankowych oraz typowym obrazem histologicznym. W populacji pacjentów pediatrycznych postaci dziecięce autoimmunologicznego zapalenia wątroby i autoimmunologicznego stwardniającego zapalenia dróg żółciowych są wspólnie klasyfikowane jako młodzieńcza autoimmunologiczna choroba wątroby. Często może ona współistnieć z innymi zaburzeniami autoimmunologicznymi. Niniejszy artykuł ma na celu przedstawienie profilu klinicznego pacjenta pediatrycznego z pełnoobjawowym autoimmunologicznym zapaleniem wątroby, jak również dostępnych metod leczenia. Pacjent w wieku 13 lat został skierowany do szpitala specjalistycznego z powodu narastającej hipertransaminazemii. Chłopiec był hospitalizowany po raz pierwszy w szpitalu rejonowym z powodu bólu brzucha, podczas pobytu stwierdzono podwyższoną aktywność transaminaz z tendencją do wzrostu w badaniach kontrolnych. Obraz sugerował proces zapalny wątroby i dróg żółciowych. W endoskopii górnego odcinka przewodu pokarmowego opisano zmiany o charakterze przewlekłego zapalenia błony śluzowej żołądka i gastropatii wrotnej. Leczenie obejmowało kwas tiazolidynodiowy, witaminę K, kwas ursodeoksycholowy, rifaksyminę, ciprofloksacynę i inhibitory pompy protonowej. W terapii, mającej na celu utrzymanie immunosupresji i tłumienie odpowiedzi zapalnej, która prowadzi do marskości wątroby, najczęściej

wykorzystuje się steroidy pod osłoną inhibitora pompy protonowej lub alternatywnie mykofenolan mofetylu, cyklosporynę A, takrolimus i terapię biologiczną. Kwas ursodeoksycholowy wykazuje również właściwości immunomodulujące, umożliwiając zmniejszenie dawki steroidów i ryzyko wystąpienia działań niepożądanych terapii.

Słowa kluczowe: pediatria, autoprzeciwciała, autoimmunologiczne zapalenie wątroby, hipergammaglobulinemia

INTRODUCTION

Autoimmune hepatitis (AIH) is an inflammatory disease with a chronic course, typical histological picture, and high concentrations of transaminases, IgG antibodies, and tissue autoantibodies⁽¹⁾. The disease can develop in patients regardless of their age, race, and gender. In European countries, the incidence of AIH has been determined in Denmark, where it occurred with a frequency of 23.9:100,000 inhabitants in 1994–2012, with a projected increase in incidence in the following years, and in the Netherlands in the years 1967–2011 (considering the progress of AIH diagnostics), where the incidence was 18.3:100,000. In cohort studies from 2014 to 2019 in the USA, the ratio was 31.2:100,000⁽²⁾. Although the disease can develop at any age, it is most often diagnosed in middle-aged women. Factors that may contribute to the continuing increase in the number of diagnosed cases, such as environmental influences, will probably entail an increase in the ratio of women to men. This is indicated by a three-fold increase in incidence in Japan in 2016 compared to 2004, with a simultaneous change in the ratio of women to men in the country's demography from 1:6.9 in 2004 to 1:4.3 in 2016. Consequently, as the ratio of women to men grew, the incidence of AIH increased⁽³⁾. In the paediatric patient population, AIH and autoimmune sclerosing cholangitis are collectively classified as juvenile autoimmune liver disease (JAILD)⁽⁴⁾. Clinical diagnostic standards were formulated, initially for adult patients and then adapted for paediatric patients, only in the late 1990s by the International Autoimmune Hepatitis Group (IAIHG). Therefore, the number of correctly diagnosed AIH among children and, consequently, the estimated frequency of its occurrence may be significantly underestimated. According to Verma et al., the estimated incidence of AIH among children is 2 to 17 per 100,000⁽⁵⁾. It should be noted that most studies related to the symptomatology and epidemiology of AIH refer to adult patients. Similarly to adults, girls are more likely to develop the juvenile form of AIH, accounting for 60–76% of patients^(6–8).

In Poland, due to the newborn vaccination programme and prophylactic testing, the number of registered acute HBV infections (including mixed hepatitis B and hepatitis C virus infections) ranged from 649 in 2005 to 45 in 2019⁽⁹⁾. Also with respect to HAV, Poland is among the European countries with the lowest incidence, with the exception of the international epidemic in 2017, which mainly affected adults⁽¹⁰⁾. In a study showing trends in HCV incidence (including mixed infections with HBV) in Poland from 2009

to 2021, the youngest age group (0–14 years old) accounted for about 2% of all diagnosed cases, with a clear downward trend⁽¹¹⁾.

The ongoing decline of the incidence of viral hepatitis in the paediatric population should be associated with a primary expansion of the differential diagnosis to include increasingly diagnosed AIH among paediatric patients with chronic hypertransaminasaemia.

AIH may co-occur with other autoimmune disorders (Hashimoto's disease, type 1 diabetes, systemic lupus erythematosus or coeliac disease in up to 20% of patients). A positive family history of autoimmune diseases occurs in up to 40% of patients with AIH⁽¹²⁾. There are two types of AIH:

- AIH-1 – occurs more frequently; presence of ANA antinuclear antibodies or anti-SMA smooth muscle antibodies. Most often, symptoms are diagnosed at one of two peaks: in adolescence or around the age of 40.
- AIH-2 – confirmed by the presence of anti-liver and kidney anti-microsomal antibodies (anti-LKM-1) and anti-cytosolic antibodies (anti-LC1); most common in newborns and young adults^(12,13).

The differences between the types of AIH are summarised in Tab. 1.

Muratori et al. (2015) suggests that the division into subtypes is unjustified due to the fluid boundaries between these diagnoses. This is justified by:

- the reported presence of ANA and SMA antibodies in patients with diagnosed AIH-2;
- the same distribution of alleles constituting the main risk factor from a genetic point of view among patients regardless of the identified subtype;
- reports of an asymptomatic course of the disease in adult patients with AIH-2, which should have an acute course in childhood, and the same therapy for both subtypes⁽¹⁴⁾.

Feature	AIH type 1	AIH type 2
Frequency	95%	5%
Antibody ANA	Present	Not present
Antibody ASMA	Present	Not present
At what time of life	• Adolescence • About 40 years	• Newborns • Young adults
Antibody anti-LKM-1	Not present	Present
Antibody anti-LC1	Not present	Present

Tab. 1. Typical classification images of AIH types 1 and 2, considering the most diagnostically significant differences

Therefore, the authors suggest stopping at diagnosing AIH, without further defining the subtype⁽¹⁴⁾. Together with primary biliary cirrhosis (PBC) and primary sclerosing cholangitis (PSC), AIH is classified as a major autoimmune liver disorder. The coexistence of individual features of these diseases is referred to as overlap syndromes. They are characterised by deviations in laboratory results and histopathological findings that combine structures occurring in different entities. In children, the most common overlap syndrome is the AIH-PSC syndrome⁽¹³⁾. There are also borderline syndromes in which hepatitis is accompanied by autoimmune symptoms, but not all AIH criteria are met. The clinical picture of AIH is diverse – from asymptomatic, through chronic, ending with acute liver failure. The initial symptoms may be non-specific, including malaise, nausea, vomiting or abdominal pain, but sometimes the diagnosis is based solely on abnormal liver function test results. In the chronic course of AIH, the first symptoms may be a consequence of portal hypertension developing due to structural changes. These include, among others, bleeding from the gastrointestinal tract due to varicose veins of the oesophagus or the fundus of the stomach, or splenomegaly. Approximately 50% of cases in the paediatric population present with acute viral hepatitis. The occurrence of individual symptoms and their severity depend on the type of AIH, but also on several genetic and epidemiological factors^(13,15).

AETIOPATHOLOGY

The aetiopathology of AIH has not been established despite noticeable connections with genetic factors (more frequent occurrence was noted in people with HLA A1B8DR3 and DR4 determinants), viral infections or toxic factors. It is worth emphasising the unique role of autoimmune processes in the liver, which, due to its physiological role, is most often exposed to contact with pathogens, toxins, allergens, and cancer cells of the body. The disorder of immune regulation is the result of primary or secondary impairment of the functions of suppressor T cells, which stimulates both cellular and humoral responses^(12,16). The histopathological picture shows numerous infiltrates of mononuclear cells and plasma cells in the portal and periportal spaces, also extending to the lobules, and the bile necrosis typical of AIH, which, however, is not a very specific symptom, and it is often absent. Liver cirrhosis develops in up to 38% of children. The literature distinguishes three main postulated mechanisms leading to the development of AIH – molecular mimicry, presentation of self-antigens, and loss of tolerance of the body's own antigens. Molecular mimicry is the phenomenon where an immune response against pathogens leads to antibodies being directed towards body proteins that are structurally similar to foreign antigens. The reaction initiated by T cells results in the development of AIH. In AIH type 2, the main target of autoimmunity is cytochrome P450 2D6 enzymes,

which are attacked by anti-LKM1 antibodies. A characteristic feature of CYP2D6 is the high similarity of the amino acid sequence to the sequence of the protein encoded by the HCV virus and other representatives of herpesviruses, which indicates the mechanism of molecular mimicry in this type. An epidemiological link between HCV infection and AIH-2 has also been described, as well as the presence of antibodies against HCV in 50% of patients with AIH-2. In murine models, the expansion of autoimmunity to homologous autoantigens is observed, while in human mimicry, the reaction more often spreads to anatomically distant tissues, in particular endocrine glands, which may, as a result, induce the development of, for example, type 1 diabetes or Addison's disease. In AIH, self-antigens may be presented to virgin CD4+ lymphocytes (TH0) by antigen-presenting cells (APCs) which connect specific proteins to the TCR receptors of the lymphocytes. Due to the large concentration of APCs in the liver, the reaction develops locally, damaging the organ's parenchyma. Virgin lymphocytes differentiate into distinct populations depending on the cytokines present in their environment. Differentiation into TH1 cells takes place in the presence of IL-12 and induces the production of IL-2 and interferon- γ (IFN γ) as well as the activation of cytotoxic CD8+ lymphocytes, secreting IFN γ and TNF after recognising the major histocompatibility complex (MHC) type I. The action of cytokines leads to progressive activation of lymphocytes additionally intensified by excessive expression of MHC I and abnormal expression of MHC II. IFN γ also stimulates monocyte differentiation, macrophage activation, and increased NK cell activity. The formation of Th2 cells is conditioned by the participation of IL-4. These lymphocytes produce IL-4 and IL-13 necessary for the transformation of B cells into plasma cells producing autoimmunoglobulins; therefore, changes in antibody titres will correlate with indicators of disease activity. With an increased presence of TGF β , IL-1 β , and IL-6, differentiation towards TH17 will dominate, which contributes to the induction of autoimmunity through the production of pro-inflammatory cytokines IL-22, IL-17, and TNF, as well as the stimulation of IL-6 secretion by hepatocytes. Other cells, such as follicular helper T cells, $\gamma\delta$ T cells or macrophages, may also be involved in liver damage occurring in AIH by the mechanism of self-antigen presentation. Loss of tolerance to self-antigens is recognised as an essential factor in the development of AIH. CD4+ regulatory T cells (population with the CD25 receptor) are responsible for the homeostasis of immune mechanisms and, therefore, the tolerance of body cells. They are formed from virgin TH0 cells in the presence of TGF β , and they constitute approximately 5–10% of lymphocytes circulating in peripheral blood. Their main function is to control the innate and specific immune responses, limiting the proliferation and effector function of autoreactive T cells through direct contact or released cytokines. Numerous publications highlight the presence of numerical and functional disorders of Tregs during AIH, as well as a noticeable correlation

between the decrease in their number and an inversely proportional increase in markers of disease activity (anti-SLA and anti-LKM1 autoantibodies). Results of impaired homeostasis associated with AIH include the loss of control over the proliferation of CD4+ and CD8+ effector cells and their reduced sensitivity to signals, ineffective elimination of pro-inflammatory cytokines by Tregs, reduced susceptibility to IL-2, and increased conversion into effector cells. Environmental factors that may contribute to the development or exacerbation of AIH with simultaneous genetic susceptibility and individual predispositions include:

- Viral infections: including HAV, HBV/HDV, HCV, HEV, EBV, CMV, and HSV-1. In AIDS patients, the development of AIH is extremely rare, but it should be considered if symptoms of hepatitis of unknown aetiology are noticed, due to the possible acute course of the disease, which may be life-threatening.
- Medications: in individuals with a genetic predisposition, the inflammatory factors for the development of AIH may include oxyphenisatine, methyldopa, ornidazole, diclofenac or antiretroviral drugs.
- Alcohol: an environmental factor that may contribute to the development of AIH due to its metabolites stimulating the autoimmune response of the liver.
- Xenobiotics: chemical compounds and toxins that may be found, for example, in household cleaning agents (tetrachloromethane)^(16–18).

CASE REPORT

A 13-year-old male patient was referred to a specialist hospital due to elevated levels of aminotransferases. The boy born was born of G II, P II, at 40 HBD, with an Apgar score of 10, with a birth weight of 3,140 g, vaginally. His physical development in infancy was normal. The patient had a history of a traffic accident at the age of 8. No abnormalities were found during post-traumatic observation in the hospital, but liver function was not tested. In February 2020, the patient was hospitalised for the first time in a local hospital due to abdominal pain, and an elevated level of transaminases was found, with ALAT – 105 U/L and AST – 101.2 U/L (02/2020), and a tendency to increase in follow-up tests. Several infectious agents (HIV, HCV, EBV, HBV) were ruled out. Due to additional reported symptoms of gastroesophageal reflux disease, re-hospitalisation was scheduled for March 2020 to perform an upper gastrointestinal endoscopy. However, the hospitalisation did not take place due to the COVID-19 pandemic. Outpatient tests showed a further increase in enzyme activity, with AST – 603 U/L, ALT – 680 U/L, alkaline phosphatase – 384.3 U/L, GGTP – 167.3 U/L (10/2020) (then – 12/2020: ALT – 1,291.2 U/L, AST – 1,380.6 U/L). Due to recurrent epigastric pain, proton pump inhibitor (PPI) treatment was started for three months, but without improvement. The patient also began to experience frequent pain in the joints (elbows, knees, hips) along with increased warmth but without

swelling and redness. Periodically, numerous painful erosive lesions appeared in the oral cavity. The patient lost approximately 8 kg in weight in five months. He passed stool one to three times a day, with variable consistency, without pathological additions and with periodic discoloration. No fever was observed, but a parent reported the patient's depressed mood. Upon admission to the clinic, the patient's general condition was good, with normal contact, and with no signs of encephalopathy. Body weight – 36.2 kg (5 c), height – 149 cm (5 c), body mass index (BMI) – 16.3 kg/m² (14 c). On physical examination, there was no evidence of ascites, the liver was protruding two fingers under the costal arch, the spleen was palpable, and there were minor pigmentation changes on the skin. Laboratory test results were as follows: ALT – 1,060 U/L, AST – 1,710 U/L, INR – 1.36, bile acids – 88.3 µmol/L (N: 0.0–6.0 µmol/L). Coeliac disease was ruled out (IgA tissue transglutaminase: 2 RU/mL; N: 0–19,999; calprotectin <50 µg/g). A1AT deficiency was also ruled out, ceruloplasmin and copper in daily urine collection were normal, infection with other hepatotropic viruses was excluded, and increased levels of IgG and ANCA antibodies were found. General urinalysis revealed leukocyturia, and the urine culture was negative. A PCR test for SARS-CoV-2 was negative. During hospitalisation, an episode of elevated temperature (to 37.7°C) occurred, which subsided the following day. Due to pain in the right hypochondrium, increasing inflammatory parameters (C-reactive protein, procalcitonin), and suspicion of cholangitis, empirical antibiotic therapy was initiated. On the second day of hospitalisation, in addition to tenderness in the liver area, the patient reported pain and swelling of the soft tissues in the right arm. On examination, the liver was tender, protruding four fingers from under the costal arch, and the arm was painful. Abdominal ultrasound with elastography revealed:

- changes corresponding to F4 on the METAVIR scale (Fig. 1);
- disturbed intrahepatic flow;
- a gallbladder with a thickened wall and discreetly dilated intrahepatic bile ducts;
- a packet of enlarged inflammatory lymph nodes in the liver hilum.

The findings suggested an inflammatory process of the liver and bile ducts. Endoscopy of the upper gastrointestinal tract revealed chronic gastritis (telangiectasia at the cardia, excessively abundant mucous lake, swollen folds of the body, numerous erosions) and portal gastropathy. Biopsies were taken from the gastric and duodenal mucosa. Magnetic resonance cholangiopancreatography (MRCP) was performed to exclude primary sclerosing cholangitis (PSC) (Fig. 2). Treatment included thiazolidinecarboxylic acid, vitamin K, ursodeoxycholic acid, rifaximin, ciprofloxacin, and PPIs. Liver biopsy revealed:

- dense, extensive lymphocytic infiltrates in all spaces, with a clear admixture of plasma cells and eosinophils, obscuring the focal structure of the parenchyma, disrupting the spatial structure (high-grade interface hepatitis);

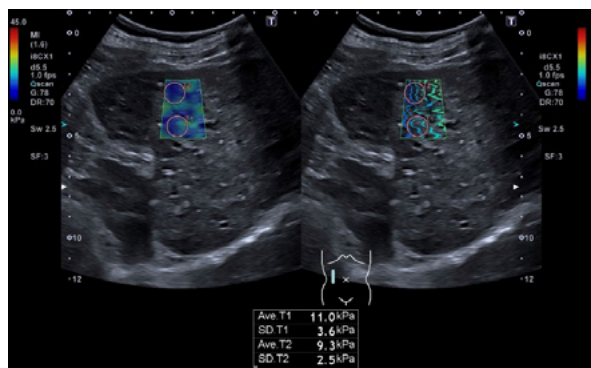


Fig. 1. Unequally elevated elasticity indices corresponding to F4 on the METAVIR scale

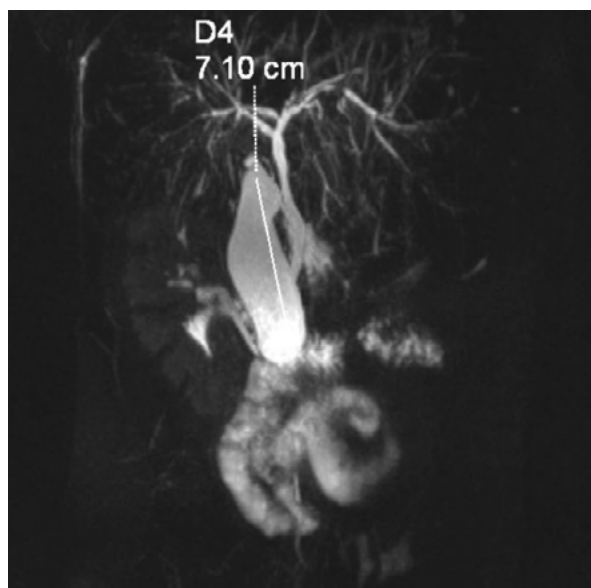


Fig. 2. MRCP: Common bile duct (CBD) and common hepatic duct (CHD) non-dilated with an irregular outline, hepatic bile ducts slightly dilated, no deposits in the bile. The cholangiogram excluded primary sclerosing cholangitis, which is the main problem in differentiation

- necrosis of hepatocyte clusters in the portal area;
- slight intralobular inflammatory activity;
- visible thin-band fibrosis;
- individual hepatocytes with features of feathery cytoplasmic degeneration;
- grading according to the Histological Activity Index (HAI): 2; staging according to HAI: 1–2; METAVIR: 2; Ishak: 2; Dixon: 0.

AIH (ICD-10: K73.2) was diagnosed, with the above features being characteristic.

The patient was discharged with the following recommendations: prednisone, ursodeoxycholic acid, ciprofloxacin omeprazole, supplementation of fat-soluble vitamins (A, D, E, K).

Follow-up tests carried out over the next two months after discharge showed a tendency to normalisation of the levels of transaminases and bilirubin. The pain around the right costal arch resolved, and there was no hepatomegaly on the

ultrasound image. The patient remains under the care of a gastroenterology outpatient clinic. One year after the diagnosis, the patient is on prednisone 60 mg/d in reduction doses, and azathioprine (AZA) 1.5 mg/d was added under 6-thioguanine (6-TG) monitoring.

DISCUSSION

The goals of AIH treatment are to decrease inflammation and to stop the disease from progressing to liver cirrhosis and decompensation⁽¹⁶⁾. Treatment is usually divided into two phases: induction and maintenance. Remission is considered attained when there are no observable clinical symptoms and liver damage markers, and immunoglobulin G levels have returned to normal. In children, achieving remission may also involve ensuring low levels of autoantibody titres. It is not known whether patients (HAI) <3, and no cirrhosis benefit from drug therapy, as testing is mainly performed on patients with moderate to severe disease⁽¹⁷⁾. Not starting pharmacotherapy may be considered in elderly patients with many comorbidities, however, it is recommended to start treatment in all situations, except for significant contraindications. Without treatment, regular monitoring of transaminase and immunoglobulin G levels should be checked every three to six months to detect possible exacerbation of the disease. Non-invasive methods, such as transient elastography, can also be used to measure liver fibrosis. The pillar of AIH therapy is immunosuppression⁽¹²⁾, with steroid therapy recognised as the gold standard. Therapy should be usually conducted under protection of PPIs. During pharmacotherapy, side effects may occur resulting from the mechanism of steroids. These include, among others, weight gain, steroid-induced diabetes, arterial hypertension, emotional instability, or psychosis; hence, the aim is to reduce the dose of the administered steroid drug. AZA is usually added to therapy as the so-called steroid-sparing agent (a drug that reduces side effects occurring during steroid therapy). There are differences between guidelines issued by the European Association for the Study of the Liver (EASL) and the American Association for the Study of Liver Diseases (AASLD)⁽¹⁸⁾, mainly with mild disease (ALT less than three times the reference range, HAI all situations, except for significant contraindications. If left untreated, the usual monitoring process involves giving an initial dose of prednisone bolus at 2 mg/kg of body weight (up to 40–60 mg). This is typically combined with AZA at a daily dose of 50 mg. The AASLD recommends starting AZA and corticosteroid treatment concurrently, while the EASL guidelines propose a gradual introduction of AZA, beginning two weeks after corticosteroids. Additionally, EASL guidelines suggest that if patients are likely to experience side effects specific to steroids, remission can be induced by replacing prednisolone with budesonide at an initial dose of 9 mg/day⁽¹⁶⁾. The moment at which AZA is included in the treatment regimen may change and depend on the preferences of the attending physician. Some start AZA in parallel with steroids, and others wait until the level of plasma

aminotransferases increases, but it is not advisable to start AZA if the patient presents with acute liver failure. The dose of AZA usually used in the treatment of children is 1–2 mg/kg body weight/day (maximum 50 mg at the beginning of therapy) and is then personalised in relation to the concentration of the active metabolite – 6-TG. The goal of therapy is to decrease the level of 6-TG because elevated levels of the substance may promote the formation of harmful metabolites leading to liver damage. When 6-TG levels are high, co-administration of allopurinol can redirect the metabolism of thiopurines back to the normal pathway, preventing acute liver failure or cirrhosis. The usual dose of AZA in treating children may lead to myelotoxicity. In some cases, AZA treatment could be problematic due to changes in drug metabolism, and restoring effective therapy for AIH becomes necessary. Pancreatitis is an undesirable effect of AZA. It is not dependent on the dose, and monitoring the enzyme thiopurine methyltransferase (TPMT) in erythrocytes does not guarantee effective prevention. When 6-TG is at the normal therapeutic level, and liver enzymes are within the healthy range, doctors may choose to completely stop steroid treatment. However, some clinicians may prefer to continue a combination of low-dose prednisone and AZA. Since it is crucial to ensure a child's proper growth, many doctors prefer using AZA alone whenever feasible⁽¹²⁾.

Treatment of AIH may also be provided by an alternative therapy to steroids or second-line therapy, as for almost 20% of patients with AIH, conventional therapy will either fail or not be tolerated at some point^(19,20). Mycophenolate mofetil (MMF) is a new generation non-competitive inhibitor of inosine monophosphate dehydrogenase, which restricts purine synthesis. MMF has been successfully employed as an immunosuppressive and antiproliferative medication because, unlike other cells, the proliferation of T and B cells is primarily dependent on purine synthesis. In individuals with AIH who have not received any prior treatment, the combination of MMF and prednisolone has shown effectiveness and safety in bringing about disease remission. Standard treatment with MMF and prednisolone allows for higher remission rates and a decrease in transaminase is important because AIH mainly affects young women⁽²¹⁾. Cyclosporine A and tacrolimus belong to the calcineurin inhibitor group, commonly used for immunosuppression and considered comparable in strength to the standard steroid therapy for AIH. Concurrently, cyclosporine A is effectively employed as an alternative treatment for AIH patients who are unresponsive to AZA and steroids. Unfortunately, cyclosporine A comes with various side effects, including nephrotoxicity, neurotoxicity, heightened susceptibility to infections, and an increased risk of malignancies with prolonged usage. Animal studies also suggest that cyclosporine A may trigger autoimmunity and elevate IgG levels. For patients with corticosteroid-resistant disease or intolerance to AZA, MMF has proven successful as a second-line or salvage therapy. It is important to note that MMF carries significant side effects, including gastrointestinal symptoms, and because of its potential to cause birth defects,

it cannot be prescribed to pregnant women. This is particularly crucial because MMF acts on Treg activation and IL-2 production, impacting the immune system.

Evidence from clinical studies indicates that cyclosporine A can be a viable choice as the first-line treatment for patients with AIH who require pharmacotherapy. Its immunosuppressive potency surpasses its anti-inflammatory capabilities, making it less suitable for AIH treatment. While tacrolimus is a more potent calcineurin inhibitor than cyclosporine, and has fewer nephrotoxic side effects, current clinical data do not endorse its use as a primary treatment for AIH. However, emerging studies focusing on steroid-resistant patients have shown reduced inflammation and fibrosis progression, as well as biochemical and histological improvement after pharmacotherapy with tacrolimus⁽²²⁾. Biological therapy using monoclonal antibodies, e.g. rituximab and infliximab, has been used as an effective treatment in patients with refractory or difficult-to-treat AIH for a relatively short time. Although AIH is classified as an autoimmune disease mediated by T lymphocytes, rituximab, which is a monoclonal antibody that destroys B lymphocytes, has shown beneficial effects in treatment resistant AIH. One possible explanation for this effect may be the active role of B cells in antigen presentation and T cell suppression. Clinical side effects of rituximab include an increased incidence of infections, which in some circumstances led to discontinuation of treatment in patients with AIH. Infliximab is a humanised chimeric monoclonal antibody directed against the pro-inflammatory cytokine TNF- α . So far, it has been used mainly as a salvage therapy in patients with AIH. Infliximab may cause symptoms resembling AIH hepatotoxicity and other immune-related disorders, therefore it should be used with great caution only in specialised centres with extensive experience in the treatment and monitoring of AIH⁽²³⁾.

Ursodeoxycholic acid (UDCA) is used as the treatment of choice in patients with primary cholangitis but has also been shown to have immunomodulatory properties and may inhibit immunoglobulin production in a concentration-dependent manner, which is beneficial in patients with AIH, allowing for additional reduction doses of steroids. A recent study on Japanese patients with histologically and serologically mild AIH even revealed that UDCA monotherapy could achieve and maintain normalization of ALT levels in 71%⁽²⁴⁾. The remission of AIH is rare, and in most patients, achieving remission is not possible. Therefore, lifelong maintenance therapy is typically necessary (aiming for the lowest possible dose of steroids with or without AZA to achieve and sustain remission) or patient monitoring (every three months in the first year, and every six months afterwards), since disease relapse can occur at any time. In a small proportion of patients (10–20%), where a reduction in the dose of all immunosuppressive drugs is possible and stable remission is maintained without immunosuppressive drugs, a relapse is still possible even after many years without the disease. Thus, regular monitoring is recommended for patients throughout their lives. Generally, there is a trend that the longer the remission without

medication, the lower the risk of relapse, but there have been literature reports of disease relapse even after 20 years of remission⁽¹⁷⁾.

CONCLUSION

The patient in the reported case presented with a wide range of clinical symptoms that can be expected in a paediatric patient with AIH. Considering the increasing number of diagnosed autoimmune diseases, as well as their mutual co-existence and overlap syndromes in children, the difficulties involved in establishing the diagnosis and a decrease in the incidence of viral hepatitis, AIH should be among the diagnoses considered in clinical practice in patients presenting symptoms including acute hepatitis or only an increased level of transaminases with a simultaneous exclusion of infectious agents and a positive history of other autoimmune diseases. It should be remembered that negative anti-LKM-1, anti-LC1 or ANA antibodies in a single blood test do not make it possible to exclude autoimmune aggression. Therapy aimed at maintaining immunosuppression and inhibiting the inflammatory reaction leading to liver cirrhosis is usually based on steroids administered alongside PPIs or, alternatively, mycophenolate mofetil, cyclosporine A, tacrolimus, and biological therapy. Ursodeoxycholic acid also has immunomodulatory properties and, by allowing a reduction of steroid doses, it reduces the likelihood of adverse effects of therapy. What needs to be highlighted in the discussed case is the delayed diagnosis of AIH in the patient, which was probably related to the then prevailing COVID-19 pandemic and the associated limited access to the health care system.

Conflict of interest

The authors do not report any financial or personal connections with other persons or organisations which might negatively affect the content of this publication and/or claim authorship rights to this publication.

Author contribution

Original concept of study: HPS, JB, TP. Collection, recording and/or compilation of data: HPS, JW. Analysis and interpretation of data: MW, JW. Writing of manuscript: HPS, MW, TP. Critical review of manuscript: JB, TP.

References

1. Mieli-Vergani G, Vergani D: Autoimmune liver disease. In: D'Antiga L (ed.): *Pediatric Hepatology and Liver Transplantation*. Springer Cham, 2019: 175–199.
2. Tunio NA, Mansoor E, Sheriff MZ et al.: Epidemiology of autoimmune hepatitis (AIH) in the United States between 2014 and 2019: a population-based national study. *J Clin Gastroenterol* 2021; 55: 903–910.
3. Komori A: Recent updates on the management of autoimmune hepatitis. *Clin Mol Hepatol* 2021; 27: 58–69.
4. de Boer YS, Liberal R, Vergani D et al.: Real-world management of juvenile autoimmune liver disease. *United European Gastroenterol J* 2018; 6: 1032–1038.
5. Verma S, Torbenson M, Thuluvath PJ: The impact of ethnicity on the natural history of autoimmune hepatitis. *Hepatology* 2007; 46: 1828–1835.
6. Pathak S, Kamat D: Autoimmune hepatitis in children. *Pediatr Ann* 2018; 47: e81–e86.
7. Dehghani SM, Haghighat M, Imanieh MH et al.: Autoimmune hepatitis in children: experiences in a tertiary center. *Iran J Pediatr* 2013; 23: 302–308.
8. Mack CL, Adams D, Assis DN et al.: Diagnosis and management of autoimmune hepatitis in adults and children: 2019 practice guidance and guidelines from the American Association for the Study of Liver Diseases. *Hepatology* 2020; 72: 671–722.
9. Stawinska-Witoszynska B, Klos J, Moryson W et al.: Trends in the incidence of acute hepatitis B in the Polish population and their determinants. *Medicina (Kaunas)* 2021; 57: 738.
10. Narodowy Instytut Zdrowia Publicznego – Państwowy Zakład Higieny: Raport końcowy za lata 2017–2020 z realizacji zadania 3 pkt 2.1. podpunkt 6c. Identyfikacja oraz charakterystyka biologicznych czynników chorobotwórczych w zakresie ich cech genotypowych i fenotypowych, w tym ich lekooporność – Charakterystyka szczepów wirusa zapalenia wątroby typu A (HAV) występujących w Polsce. Available from: <https://www.pzh.gov.pl/wp-content/uploads/2021/03/RAPORT-KONCOWY-Identyfikacja-oraz-charakterystyka-biologicznych-czynnikow-chorobotworczych-w-zakresie-ich-cech-genotypowych-i-fenotypowych-w-tym-ich-lekoopornosc.pdf> [cited 13 January 2024].
11. Genowska A, Zarębska-Michaluk D, Strukcinskiene B et al.: Changing epidemiological patterns of infection and mortality due to hepatitis C virus in Poland. *J Clin Med* 2023; 12: 3922.
12. Kerker N, Chan A: Autoimmune hepatitis, sclerosing cholangitis, and autoimmune sclerosing cholangitis or overlap syndrome. *Clin Liver Dis* 2018; 22: 689–702.
13. Rust C, Beuers U: Overlap syndromes among autoimmune liver diseases. *World J Gastroenterol* 2008; 14: 3368–3373.
14. Muratori P, Lalanne C, Fabbri A et al.: Type 1 and type 2 autoimmune hepatitis in adults share the same clinical phenotype. *Aliment Pharmacol Ther* 2015; 41: 1281–1287.
15. Sokollik C, McLinn VA, Vergani D et al.: Juvenile autoimmune hepatitis: a comprehensive review. *J Autoimmun* 2018; 95: 69–76.
16. Kia L, Beattie A, Green RM: Autoimmune hepatitis in patients with human immunodeficiency virus (HIV): case reports of a rare, but important diagnosis with therapeutic implications. *Medicine (Baltimore)* 2017; 96: e6011.
17. Mieli-Vergani G, Vergani D, Czaja A et al.: Autoimmune hepatitis. *Nat Rev Dis Primers* 2018; 4: 18017.
18. Zachou K, Arvaniti P, Lyberopoulou A et al.: Impact of genetic and environmental factors on autoimmune hepatitis. *J Transl Autoimmun* 2021; 4: 100125.
19. Konturek SJ: *Gastroenterologia i hepatologia kliniczna*. Wydawnictwo Lekarskie PZWL, Warszawa 2006: 719–723.
20. Terziroli Beretta-Piccoli B, Mieli-Vergani G, Vergani D: Autoimmune hepatitis: standard treatment and systematic review of alternative treatments. *World J Gastroenterol* 2017; 23: 6030–6048.
21. Sharzei K, Huang MA, Schreiberman IR et al.: Mycophenolate mofetil for the treatment of autoimmune hepatitis in patients refractory or intolerant to conventional therapy. *Can J Gastroenterol* 2010; 24: 588–592.
22. Sucher E, Sucher R, Gradistanac T et al.: Autoimmune hepatitis – immunologically triggered liver pathogenesis – diagnostic and therapeutic strategies. *J Immunol Res* 2019; 2019: 943704.
23. Pape S, Schramm C, Gevers TJ: Clinical management of autoimmune hepatitis. *United European Gastroenterol J* 2019; 7: 1156–1163.
24. Torisu Y, Nakano M, Takano K et al.: Clinical usefulness of ursodeoxycholic acid for Japanese patients with autoimmune hepatitis. *World J Hepatol* 2017; 9: 57–63.