

Jeyasakthy Saniasiaya¹, Irfan Mohamad², Sanjeevan Nadarajah²

Ostry ropień zagardłowy imitujący ropień okołomigdałkowy u dziecka: wyzwanie diagnostyczne

Acute retropharyngeal abscess mimicking a peritonsillar abscess in a child: a diagnostic challenge

¹ Department of Otorhinolaryngology, Faculty of Medicine, Universiti Malaya, Jalan Universiti, 50603 Kuala Lumpur, Malaysia

² Department of Otorhinolaryngology – Head & Neck Surgery, School of Medical Sciences, Universiti Sains Malaysia Health Campus, 16150 Kota Bharu, Kelantan, Malaysia

Adres do korespondencji: Jeyasakthy Saniasiaya, MD, Department of Otorhinolaryngology, Faculty of Medicine, Universiti Malaya, Jalan Universiti, 50603 Kuala Lumpur, Malaysia, e-mail: shakthy_18@yahoo.com

ORCID iDs

1. Jeyasakthy Saniasiaya <https://orcid.org/0000-0003-1974-4379>
2. Irfan Mohamad <https://orcid.org/0000-0001-8572-0514>
3. Sanjeevan Nadarajah <https://orcid.org/0000-0002-1216-4016>

Streszczenie

Cel pracy: Podkreślenie znaczenia skrupulatnego badania podmiotowego i przedmiotowego oraz przedstawienie możliwości diagnostyczno-terapeutycznych u dzieci z ropniami umiejscowionymi w przestrzeni zagardłowej. **Opis przypadku:** Ropień zagardłowy często rozwija się u dzieci do 4. roku życia po przebytych zakażeniach górnych dróg oddechowych lub ucha. W obrazie klinicznym zwykle stwierdza się gorączkę, odynofagię i niedrożność dróg oddechowych. Cechy te mogą naśladować zapalenie nagłośni i zapalenie opon mózgowych, co może opóźnić podjęcie prawidłowego leczenia. W pracy przedstawiono przypadek 4-letniego chłopca, u którego wystąpiły gorączka, obrzęk szyi, dysfagia oraz kręcz szyi. Pacjent został skierowany do ośrodka autorów z podejrzeniem ropnia okołomigdałkowego. W tomografii komputerowej szyi uwidoczniła się obecność ogniska wypełnionego treścią w przestrzeni zagardłowej. U dziecka wykonano nacięcie i drenaż zmiany oraz zastosowano 2-tygodniowy cykl antybiotykoterapii. Leczenie zakończyło się sukcesem. **Wnioski:** Przedstawiony opis przypadku dowodzi, że uniknięcie zagrażających życiu powikłań zależy w dużej mierze od wczesnego rozpoznania i podjęcia niezbędnych interwencji.

Słowa kluczowe: ropień zagardłowy, dziecko, ropień okołomigdałkowy, kręcz szyi

Abstract

Aim of the study: To emphasise the importance of meticulous history taking and physical examination as well as to raise the awareness of various possibilities in the diagnosis and management of retropharyngeal abscesses in children. **Case study:** Retropharyngeal abscess commonly occurs in children under 4 years of age following upper respiratory tract infection or ear infection. Commonly, the presentation includes fever, odynophagia, and airway obstruction. The features may mimic epiglottitis and meningitis, which can delay appropriate treatment. We describe a case of a 4-year old boy who presented with fever, neck swelling, dysphagia, and torticollis. He was initially referred for a peritonsillar abscess. Computed tomography of the neck showed a collection in the retropharyngeal space. The child underwent incision and drainage, completed a 2-week course of antibiotics, and completely recovered. **Conclusion:** We highlight the importance of early diagnosis and prompt management of the condition to avoid life-threatening complications.

Keywords: retropharyngeal abscess, child, peritonsillar abscess, torticollis

INTRODUCTION

Acute retropharyngeal abscess is considered the most common deep neck space infection in children⁽¹⁾. In the paediatric population, acute retropharyngeal abscess occurs due to suppuration in the retropharyngeal lymph node which drains the nasopharynx, oropharynx, and tonsils. The classic presentation of acute retropharyngeal abscess is oropharyngeal swelling. However, unilateral oropharyngeal swelling, causing a peritonsillar bulge with uvula deviation, may also divert the clinician towards the diagnosis of peritonsillar abscess.

CASE REPORT

A 4-year-old boy with a history of bronchiolitis was referred for left peritonsillar abscess by an Emergency Department physician. The child presented with a 2-day history of high-grade fever, left-sided neck swelling, dysphagia, and torticollis. The parents claimed that the symptoms had worsened rapidly overnight and child refused any oral intake. He had no history of similar symptoms, recent ear discharge, recurrent sore throat, recurrent nasal symptoms, trauma or tuberculosis. He was not receiving any medication or treatment at the time of the examination.

Upon general inspection, the child looked lethargic, febrile with a body temperature of 38°C, mildly dehydrated and tachycardic. There was no audible noisy breathing as the child was sitting comfortably under room air. The boy kept his neck flexed at all times, and the range of neck movement was limited. Nasal examination revealed no abnormality, and the cold spatula test performed was equal and patent bilaterally. Oropharyngeal examination revealed bulging over the left side of the posterior pharyngeal wall and the left peritonsillar region. The tonsils were bilaterally symmetrically enlarged, mildly injected, with no evidence of pus or exudate. No trismus was noted during the examination, either.

Neck examination revealed left-sided neck swelling, measuring 2 × 3 cm, occupying level II, tender, firm, non-erythematous, non-mobile, and non-pulsatile. There were no other palpable masses in the head and neck or any other parts of the body. Otoloscopic examination was normal. On auscultation, the lungs were bilaterally equal and clear. Other systemic examinations were normal. Full blood count revealed a significant increase in white blood cells with normal electrolytes. The preliminary diagnosis was left peritonsillar abscess. A computed tomography (CT) examination of the neck was performed, since the presence of torticollis and lateral neck swelling led to the suspicion of a left parapharyngeal abscess.

A CT scan of the neck revealed a retropharyngeal lesion at the level of the posterior choanae, more to the left, measuring 4.6 × 2.7 × 1.8 cm, with multiple loculated hypodensities within the lesion suggestive of an abscess collection mainly on the left side, extending from the base of the skull

as far as the level of the thyroid bed (Figs. 1, 2). Anteriorly, the left parapharyngeal space was narrowed due to mass effect. Medially, the lesion caused mass effect by pushing the oropharynx to the right, which may have misled the diagnosis of a peritonsillar abscess. Multiple matted nodes were seen over the left neck, involving levels II, III, and IV. Thus, the diagnosis of a retropharyngeal abscess with multiple lymphadenopathies was made. The child was started on intravenous amoxicillin/clavulanic acid.

Incision and drainage were commenced under general anaesthesia via an intraoral approach. Intraoperatively, a bulge was seen occupying the left side of the posterior pharyngeal wall, pushing the uvula to the right side. The tonsils were bilaterally moderately enlarged, non-inflamed, with no exudates seen. A vertical incision was made over the bulge, however no pus was drained. Postoperatively, the child was well, and the lateral neck swelling appeared to be slowly reducing in size. Intraorally, the bulge over the posterior pharyngeal wall seemed to be resolving, with no signs of pus discharge. The range of neck movement improved.

The child was monitored for 2 days with continuation of intravenous antibiotics and close observations. Over the next 48 hours, the boy's general condition improved tremendously. He was active, afebrile, and eating well. The range of neck movement improved. The child was discharged home with a one-week course of oral antibiotics, and an appointment was scheduled in 2 weeks' time. A follow-up intraoral examination two weeks later showed a well-resolved infection with normal mucosa.

DISCUSSION

Retropharyngeal space is one of the deep neck spaces lying behind the pharynx between the buccopharyngeal fascia and prevertebral fascia, extending from the base of the skull as far as the tracheal bifurcation⁽²⁾. This space is divided into two lateral compartments also known as the space of Gillette by a fibrous raphe. The space contains lymph nodes which are more prominent in young children and regress by the age of 4 or 5 years.

Acute retropharyngeal abscess in children is usually secondary to upper respiratory infections⁽³⁾. Rarely, retropharyngeal abscess can occur as a complication of mastoid abscess⁽⁴⁾. Tonsils may be regarded as a source of infection, as 80% of children presenting with retropharyngeal abscess had tonsils that were enlarged, and it is never found in children who had their tonsils removed⁽⁵⁾.

The clinical presentation of acute retropharyngeal abscess is highly variable and non-specific, as seen in our patient, and may also mimic epiglottitis or meningitis. In the reported case, it mimicked a peritonsillar abscess. The most common symptoms include fever, neck pain, dysphagia or odynophagia, and neck swelling⁽⁶⁾. Regarding the clinical signs, the majority of patients present with oropharyngeal swelling and limitation of

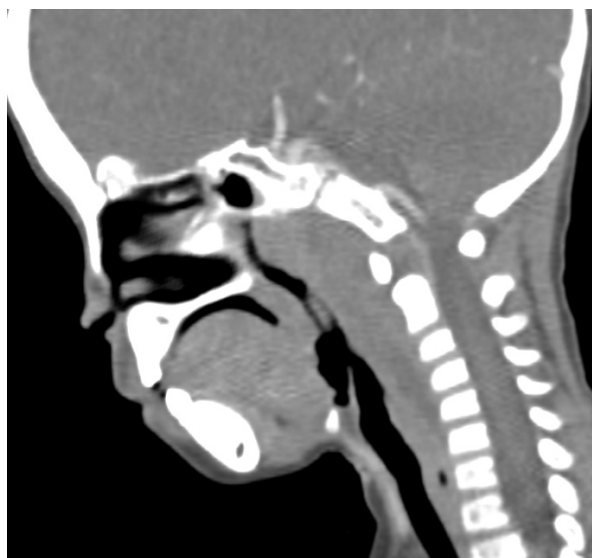

Fig. 1. Fullness of the retropharyngeal space at the level of the nasopharynx and oropharynx

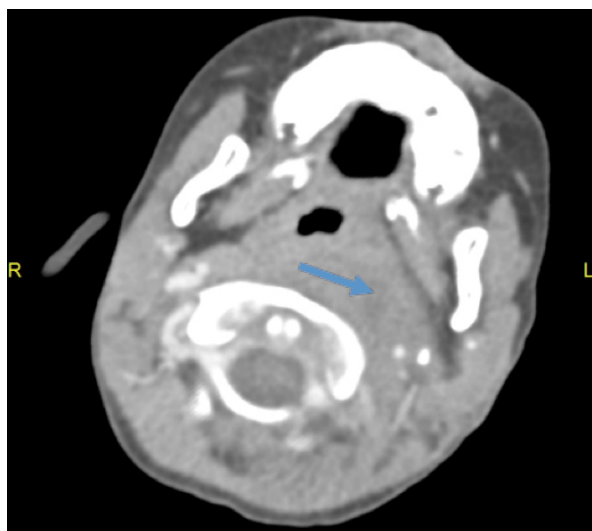


Fig. 2. Fullness of the retropharyngeal space with poor plane with prevertebral space, more prominent on the left side, causing mass effect and obliteration of the left parapharyngeal space

neck movement, cervical swelling or lymphadenopathy, and torticollis⁽⁶⁾. As for the oropharyngeal swelling, a unilateral bulge usually points towards an acute presentation, as chronic retropharyngeal abscess usually presents with a midline bulge. The bulge may push the peritonsillar area anteriorly, which appears as a swelling that mimics a peritonsillar abscess.

The diagnosis of retropharyngeal abscess is done based on a clinical suspicion guided by imaging studies. Imaging modalities used in diagnosing retropharyngeal abscess include widened prevertebral soft tissue on the lateral neck radiograph, computed tomography scan of the neck, and magnetic resonance imaging. Even though a plain lateral soft tissue neck radiograph contributes

greatly to the diagnosis, its drawback is that it has a false positive rate of 30% in the detection of abscess⁽⁶⁾. In addition to that, a radiograph must be obtained in the true lateral position with maximum extension and in the inspiratory phase of respiration⁽⁶⁾, which may be difficult in children, as in our case. Measurements greater than 7 mm at C2 and 14 mm at C7 in children, and 22 mm in adults, are strongly suggestive of retropharyngeal abscess on lateral neck radiographs⁽⁷⁾. CT scan has a sensitivity of 90% and specificity of 60%⁽⁸⁾. However, it is unable to differentiate between an abscess and cellulitis, and has a false positive rate of 17%⁽⁶⁾. In our patient, a CT scan of the neck was done, as it enabled us to locate the abscess, its extension and relationship with the surrounding structure, and to establish a treatment regime. Even though the CT scan revealed a collection, no pus was drained intraoperatively.

The choice of medical over surgical management remains controversial issue. Vázquez López et al. suggested that the choice of treatment should depend on the general condition of the child, size of the abscess, potential complications and possible surgical accessibility⁽⁹⁾. Based on these guidelines, surgical drainage was performed in our patient on account of the size of the collection and to avoid the possible risk of abscess spread into the mediastinum. The approach for surgical drainage depends on abscess location: abscess collection above the hyoid bone allows an intraoral approach, and external drainage is the preferred option if the abscess extends below hyoid bone⁽¹⁰⁾. However, a broad-spectrum antibiotic should be started in all patients as soon as the diagnosis of a retropharyngeal abscess is made.

CONCLUSIONS

Retropharyngeal abscess is a deep neck space infection that poses an immediate life-threatening emergency if accurate diagnosis and management are delayed, especially among children. The presence of vague and non-specific signs and symptoms of acute retropharyngeal abscess may confuse the working diagnosis, particularly if imaging modalities are not available. In addition, early diagnosis and widespread use of antibiotics may not only be life-saving, but also help avoid surgical manipulations and other complications. To conclude, physicians should be aware of this condition, especially in the paediatric age group, and act promptly.

Conflict of interest

The authors do not declare any financial or personal links to other persons or organisations that could adversely affect the content of this publication or claim rights thereto.

Piśmiennictwo

1. Tan PT, Chang LY, Huang YC et al.: Deep neck infections in children. *J Microbiol Immunol Infect* 2001; 34: 287–292.
2. Ijaduola TGA: Pattern of retropharyngeal abscess in Nigerian children. *J Natl Med Assoc* 1986; 78: 71–73.
3. Soong WJ, Jeng MJ, Hwang B: Respiratory support of children with a retropharyngeal abscess with nasal CPAP. *Clin Pediatr (Phila)* 2001; 40: 55–56.
4. Mydam J, Thiagarajan P: A nine month old child with retropharyngeal abscess secondary to mastoid abscess presenting as torticollis: a case report. *Cases J* 2009; 2: 6460.
5. Guthrie D: Acute retropharyngeal abscess in childhood. *Br Med J* 1926; 2: 1174–1175.
6. Nazir KA, Fozia PA, ul Islam M et al.: Paediatric acute retropharyngeal abscesses: an experience. *Afr J Paediatr Surg* 2013; 10: 327–335.
7. Wholey MH, Bruwer AJ, Baker HL Jr: The lateral roentgenogram of the neck; with comments on the atlanto-odontoid-basion relationship. *Radiology* 1958; 71: 350–356.
8. Lalakea MI, Messner AH: Retropharyngeal abscess management in children: current practices. *Otolaryngol Head Neck Surg* 1999; 121: 398–405.
9. Vázquez López ME, González Gómez FJ, Fernández Iglesias JL et al.: [Torticollis secondary to retropharyngeal abscess]. *An Esp Pediatr* 2001; 55: 288–289.
10. Bluestone CD, Rosenfeld RM: *Surgical Atlas of Pediatric Otolaryngology*. BC Decker Inc, Hamilton, London 2002: 482–486.