© Pediatr Med Rodz 2022, 18 (3), p. 278–280
DOI: 10.15557/PiMR.2022.0042

Shalini Ramasamy[1], Jeyasakthy Saniasiaya[2],
Jennifer Lee Peak Hui[1], Zainal Azmi Zainal Abidin[1]

**Otrzymano:** 20.05.2021
**Zaakceptowano:** 27.01.2022
**Opublikowano:** 30.12.2022

# „Wilk w owczej skórze", czyli jednocześnie występujące nowotwory jamy nosowej

## Synchronous nasal mass: a wolf in sheep's disguise

[1] Department of Otorhinolaryngology, Hospital Selayang, Lebuhraya Selayang-Kepong, 68100 Batu Caves, Selangor, Malaysia
[2] Department of Otorhinolaryngology, Faculty of Medicine, University of Malaya, Jalan Universiti, 50603 Kuala Lumpur, Malaysia
Adres do korespondencji: Jeyasakthy Saniasiaya, MD, MMED (ORL–HNS), FEBORLHNS, Department of Otorhinolaryngology, Faculty of Medicine, University of Malaya, Jalan Universiti, 50603 Kuala Lumpur, Malaysia, e-mail: shakthy_18@yahoo.com

**ORCID iDs**
1. Shalini Ramasamy https://orcid.org/0000-0002-5188-8500
2. Jeyasakthy Saniasiaya https://orcid.org/0000-0003-1974-4379
3. Jennifer Lee Peak Hui https://orcid.org/0000-0002-3047-6515
4. Zainal Azmi Zainal Abidin https://orcid.org/0000-0002-9875-1368

Streszczenie

**Cel:** Zwrócenie uwagi na możliwość jednoczasowego występowania u pacjentów łagodnych oraz złośliwych nowotworów jamy nosowej. Choć brodawczak odwrócony, zwany także brodawczakiem Schneideriana, jest często występującym, łagodnym nowotworem pochodzenia nabłonkowego rozwijającym się w obszarze jam nosa i zatok przynosowych, może przysparzać otolaryngologom trudności diagnostycznych ze względu na miejscowo agresywny charakter, skłonność do nawrotów i możliwość przemiany złośliwej. Jednocześnie występująca inna zmiana w obrębie jamy nosowej dodatkowo wpływa na złożoność procesu leczenia. **Opis przypadku:** W pracy przedstawiono nietypowy przypadek równoczesnego występowania brodawczaka odwróconego oraz raka śluzowo-naskórkowego o niskim stopniu zaawansowania. Wstępna biopsja guza umiejscowionego w jamie nosowej pacjenta wskazała na brodawczaka odwróconego. W badaniu histopatologicznym wykonanym po przeprowadzeniu endoskopowej maksillektomii przyśrodkowej stwierdzono jednak obecność zarówno brodawczaka odwróconego, jak i raka śluzowo-naskórkowego o niskim stopniu zaawansowania. **Wnioski:** Klinicyści powinni mieć świadomość, że u pacjentów z łagodnymi brodawczakami odwróconymi w obrębie jam nosa i zatok przynosowych istnieje możliwość jednoczesnego występowania złośliwego guza w jamie nosowej – tak jak w opisanym przez nas przypadku.

**Słowa kluczowe:** brodawczak odwrócony jam nosa i zatok przynosowych, rak śluzowo-naskórkowy, endoskopia, resekcja endoskopowa

Abstract

**Aim:** To highlight the possibility of synchronous benign and malignant nasal masses. Schneiderian papilloma, also known as inverted papilloma, despite being a common benign epithelial sinonasal tumour, remains a conundrum to otorhinolaryngologists due to its locally aggressive nature, tendency to recur as well as potential of malignant transformation. A synchronous nasal lesion adds on to the complexity of patient management. **Case presentation:** Herein, we are reporting an unusual case of synchronous lesions: sinonasal inverted papilloma and low-grade mucoepidermoid carcinoma. Initial biopsy of the sinonasal mass revealed inverted papilloma. However, histopathological examination post endoscopic medial maxillectomy revealed evidence of both inverted papilloma and low-grade mucoepidermoid carcinoma. **Conclusion:** We want to highlight that seemingly benign sinonasal inverted papillomas ought to be taken seriously considering the possibility of a synchronous malignant nasal mass, as in our case.

**Keywords:** sinonasal inverted papilloma, mucoepidermoid carcinoma, endoscopy, endoscopic resection



© 2022 Ramasamy et al. This is an open-access article distributed under the terms of the Creative Commons Attribution-NonCommercial-NoDerivatives License (CC BY-NC-ND). Reproduction is permitted for personal, educational, non-commercial use, provided that the original article is in whole, unmodified, and properly cited.

## INTRODUCTION

Inverted papilloma (IP), which accounts for 0.4 to 4.7% of all sinonasal masses[1,2], has an incidence of 0.2 to 0.6% per 100,000 people per year. The histologically characteristic inversion of the mucosal surface extending into the underlying stroma of the papilloma led to the term "inverted"[3]. IP may occur anywhere within the nose and paranasal sinuses as well as within the upper aerodigestive tract. Mucoepidermoid carcinoma (MEC), on the other hand, is the most common malignant salivary gland neoplasm, typically affecting the parotid gland and rarely the minor salivary glands[4]. The incidence of malignant transformation of inverted papilloma has been reported to be between 5 and 15%, with synchronous carcinomatous lesion being 7.1% and metachronous carcinomatous lesion being 3.6%[5]. On the other hand, the literature on synchronous sinonasal IP and MEC is fairly sparse.

## CASE PRESENTATION

A 71-year-old man with underlying hypertension, diabetes mellitus, and prostate cancer presented to us with a two-month history of unilateral right-sided epistaxis. According to the patient, bleeding was spontaneous, painless, and subsided spontaneously. Otherwise, the patient denied any other nasal symptoms, ocular symptoms or other bleeding tendencies. He had no neck or facial swelling, no dysphagia or odynophagia, and no ear symptoms.

Upon examination, the patient was comfortable, not pale looking, and his vital signs were stable. Anterior rhinoscopy revealed congested mucosa over the right nasal cavity, with no mass seen bilaterally. Zero-degree rigid nasoendoscopy revealed a polypoidal mass occupying the right nasal cavity which, upon probing, was found to be friable and bleed upon touch. There was, however, no evidence of any polypoidal mass seen over the left nostril. Other than that, the intraoral examination was normal. His systemic examination and vital signs were also unremarkable and within the normal range. There were no abnormalities in the blood parameters, either. Biopsy of the nasal mass revealed respiratory epithelium inverting into the underlying stroma, suggesting inverted papilloma, exophytic type (Fig. 1).

Paranasal sinus computed tomography scan demonstrated an expanding heterogeneous mass occupying the right maxillary sinus, extending into the right nasal cavity and the right pterygopalatine fossa, with evidence of erosion of the right maxillary sinus wall and the right pterygoid plate (Fig. 2).

The patient then underwent right endoscopic medial maxillectomy under general anaesthesia, which was uneventful. Intraoperatively, a friable mass was noted, occupying the entire right nasal cavity, the maxillary sinus, and the area posteriorly to the nasopharynx. A small polypoidal mass arising from the posterior part of the left septal wall was removed. Histopathological examination of the mass revealed a component of inverted papilloma as well as a component of low-grade MEC, exhibiting multiple cystic spaces with abundant mucous-secreting cells (mucicarmine stain), intermediate and clear cells (Fig. 3). No nuclear pleomorphisms were noted. The focal area showed bony infiltrations by tumour cells. The patient was subsequently referred for radiotherapy.

*Fig. 1. Paranasal sinus computed tomography scan demonstrates an expanding heterogeneous mass occupying the right maxillary sinus, extending into the right nasal cavity, with evidence of erosion in the right maxillary sinus wall*

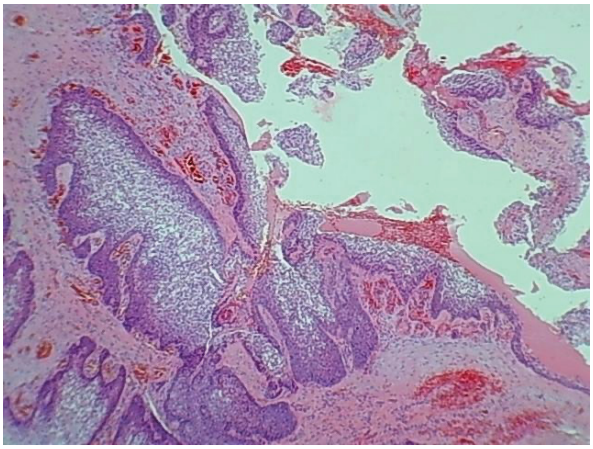

*Fig. 2. Inverted papilloma shows invagination of the epithelium into the underlying stroma*

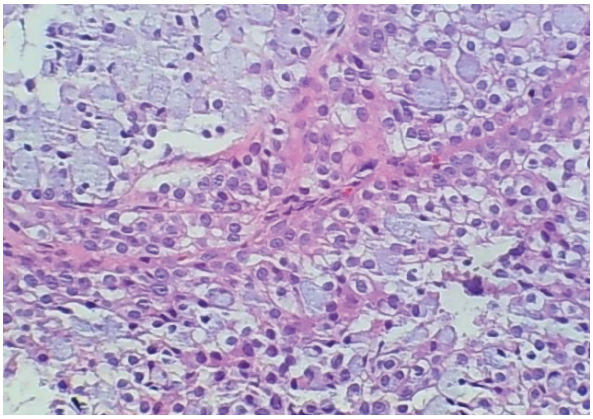

*Fig. 3. Histopathological examination of the mass reveals multiple cystic spaces with abundant mucous-secreting cells, intermediate and clear cells*



 DOI: 10.15557/PiMR.2022.0042

## DISCUSSION AND CONCLUSION

Inverted papilloma, also known as Schneiderian papilloma, transitional cell papilloma and Ringertz cell papilloma, is a type of papilloma arising in the sinonasal tract, lined by the Schneiderian epithelium; ectodermally derived respiratory mucosa. IP can be divided histologically into three types: exophytic (fungiform, septal, and squamous), inverted (inverting), and oncocytic (cylindrical cell and columnar) papillomas. In 1935, Ringertz reported on the histological evidence of the classic inverting nature of this tumour into the underlying connective tissue stroma[3]. IP occurs more frequently in men (3:1), with a peak incidence between the fifth and sixth decades of life. Although commonly unilateral, bilateral involvement has been reported in 4.9% of cases[1–3].

IP may occur in isolation or in association with chronic sinusitis. Associations with human papilloma virus (HPV) have been reported as well. Malignant transformation has been noted within two to five years[6], with a high preponderance in patients that harbour HPV types 6, 11, and 16[1,2].

IP with malignant involvement has been noted amongst the oncocytic type[7]. Our patient, as described above, demonstrated the exophytic type. Malignant transformation may occur at the time of diagnosis or later, often at the site of previous resection. MEC, epidermoid carcinoma, and sinonasal undifferentiated carcinomas have been associated with oncocytic papilloma[8].

Our patient described above was found to have a synchronous lesion of exophytic type of IP and low-grade MEC. Diagnosing low-grade MEC ex-IP is a challenge for a number of reasons. Firstly, IPs are known to have both mucous and goblet cells individually or forming small clusters, which may not be adequate for diagnosing a malignant transformation[9]. Secondly, despite being benign neoplasms, IPs are locally aggressive, causing bony erosions which may be overlooked by surgeons. Finally, cytologic atypia which can be found in IPs may lead to a synchronous malignant lesion being overlooked. In addition to that, high-grade MEC are more likely to stand out, and are thus easier to be detected early[9].

As for the management, patients with synchronous IP and low-grade MEC are treated surgically with complete resection followed by radiotherapy, similarly to our case, as margins are difficult to be estimated. Long-term follow-up is recommended to detect possible recurrence, as the disease can become quite extensive before it becomes symptomatic[5].

This case highlights the rare presentation of a synchronous sinonasal IP and low-grade MEC. Thus, it is prudent to focus on meticulous sampling due to the possibility of a synchronous lesion, as overlooking this entity may lead to recurrence and even malignant transformation, which may cause further difficulties in patient management.

**Conflict of interest**

*All authors have no conflict of interest.*

**Piśmiennictwo**

1. Seiberling K, Wormald PJ: Benign sinonasal tumors. In: Kennedy DW, Hwang PH (eds.): Rhinology. Disease of the Nose, Sinuses, and Skull Base. Thieme, New York, NY 2012: 394–408.
2. Lund VJ: Malignant sinonasal tumors. In: Kennedy DW, Hwang PH (eds.): Rhinology: Disease of the Nose, Sinuses, and Skull Base. Thieme, New York, NY 2012: 409–424.
3. Maran AGD (ed.): Logan Turner's Diseases of the Nose, Throat and Ear. 10th ed., 1988.
4. Lund VJ, Howard DJ: Nose and sinuses. In: Watkinson JC, Gilbert RW (eds.): Stell & Maran's Textbook of Head and Neck Surgery and Oncology. 5th ed., CRC Press, 2012: 754–778.
5. Mirza S, Bradley PJ, Acharya A et al.: Sinonasal inverted papillomas: recurrence, and synchronous and metachronous malignancy. J Laryngol Otol 2007; 121: 857–864.
6. Lin GC, Akkina S, Chinn S et al.: Sinonasal inverted papilloma: prognostic factors with emphasis on resection margins. J Neurol Surg B Skull Base 2014; 75: 140–146.
7. Vorasubin N, Vira D, Suh JD et al.: Schneiderian papillomas: comparative review of exophytic, oncocytic, and inverted types. Am J Rhinol Allergy 2013; 27: 287–292.
8. Khandekar S, Dive A, Mishra R et al.: Sinonasal inverted papilloma: a case report and mini review of histopathological features. J Oral Maxillofac Pathol 2015; 19: 405.
9. Hyrcza MD, Gilbert RW, Yu E et al.: Mucoepidermoid carcinoma ex-inverted papilloma. Diagn Histopathol 2015; 21: 212–215.



DOI: 10.15557/PiMR.2022.0042