

Wan Nur Anis Wan Draman^{1,2}, Hamizah Ismail³, Hashimah Ismail³,
Nik Khairani Nik Mohamad³, Irfan Mohamad^{1,2}

Received: 16.07.2018
Accepted: 31.10.2018
Published: 31.05.2019

Intranasal button battery: a case series

Bateria guzikowa w jamie nosowej – seria przypadków

¹ Department of Otorhinolaryngology – Head & Neck Surgery, School of Medical Sciences, Universiti Sains Malaysia Health Campus, 16150, Kubang Kerian, Kelantan, Malaysia

² Hospital Universiti Sains Malaysia, Health Campus USM, 16150, Kubang Kerian, Kelantan, Malaysia

³ Department of Otorhinolaryngology – Head & Neck Surgery, Hospital Raja Perempuan Zainab II, 15586 Kota Bharu, Kelantan, Malaysia

Correspondence: Wan Nur Anis Wan Draman, MD, Department of Otorhinolaryngology – Head & Neck Surgery, School of Medical Sciences, Universiti Sains Malaysia Health Campus, 16150, Kubang Kerian, Kelantan, Malaysia, e-mail: nuranisarman@gmail.com

Abstract

Intranasal foreign bodies are a common occurrence in children that may be either accidental or self-induced. The most vulnerable age is between 6 months and 4 years, when children tend to explore new objects. Button batteries as foreign bodies in the nasal cavity are rarely seen but common in the paediatric age group; and therefore they represent a growing danger. They are hazardous as they can cause liquefaction necrosis with subsequent severe local tissue destruction. In the case of diagnostic uncertainty regarding the precise nature of a metallic looking foreign body in the nose, a high index of suspicion should be retained for the possibility of a button battery and urgent removal should be undertaken. We present three cases of intranasal button battery to emphasise their hazards of impaction and the value of early diagnosis and treatment, which can prevent severe local tissue damage resulting in late sequelae, such as septal perforation.

Keywords: foreign body, nose, button battery, nasal septal perforation

Streszczenie

W grupie pacjentów pediatrycznych sytuacje przypadkowego lub zamierzonego wprowadzenia ciała obcego do jamy nosowej są dość częste. Zwykle dotyczą dzieci w wieku od 6 miesięcy do 4 lat – z uwagi na ich skłonność do poznawania nowych przedmiotów. Choć baterie guzikowe jako ciała obce w jamie nosowej występują w praktyce klinicznej rzadko, są one powszechne w środowisku dzieci i mogą być bardzo groźne. Niebezpieczeństwo to wynika z możliwości wywołania martwicy rozplywnej prowadzącej do poważnego miejscowego uszkodzenia tkanek. W przypadku niepewności diagnostycznej dotyczącej charakteru ciała obcego znajdującego się w jamie nosowej należy mieć na uwadze, iż może nią być bateria guzikowa, i niezwłocznie je usunąć. W pracy przedstawiono trzy przypadki zaklinowania baterii guzikowej w jamie nosowej w celu podkreślenia związanego z tym niebezpieczeństwa oraz znaczenia wczesnego rozpoznania i leczenia. Niezwłoczna interwencja może zapobiec poważnemu miejscowemu uszkodzeniu tkanek prowadzącemu do późnych powikłań, takich jak perforacja przegrody nosowej.

Słowa kluczowe: ciało obce, jama nosowa, bateria guzikowa, perforacja przegrody nosowej

INTRODUCTION

Button batteries are increasingly used in many electrical devices like toys, watches, calculators, hearing aids and other electronic instruments. They are composed of alkaline contents and can generate local currents resulting in thermal burns and production of more alkaline materials through electrolysis, in which may cause extensive damage to the surrounding mucosa⁽¹⁾. Despite improvement in the safety design of the products, children are still able to remove these batteries from devices. Being small, they can be easily inserted into various orifices such as the nose, ears and mouth^(1,2). In addition, their smooth and shiny appearance makes them quite attractive and noticeable to children⁽³⁾.

A button battery found as a foreign body in the nasal cavity is rare and it is most commonly found in children between the ages of 2 and 5 years⁽⁴⁾. It is an otorhinolaryngological emergency. Delayed removal of button batteries can lead to severe damage, necrosis, and perforation of the nasal septum, intranasal synechiae, and nasal deformity⁽⁵⁾.

Since it may be difficult to ascertain the nature of a foreign body in a child, delayed diagnosis and long-term complications are possible. Metallic looking foreign bodies may be button batteries, despite no clear history of insertion. Plain radiographs in anteroposterior and lateral views can help make the diagnosis by their distinctive bilaminar structure appearing as a “double-ring” or “halo.”

CASE 1

A 5-year-old boy presented with bilateral greenish mucopurulent foul smelling nasal discharge lasting for 3 weeks, accompanied by minimal occasional blood-stained discharge, fever and cough. He was treated for acute rhinosinusitis. There was a delay in diagnosing intranasal button battery due to unusual presentation mimicking acute rhinosinusitis. On anterior rhinoscopy examination, there was greenish mucopurulent foul smelling discharge

seen in both nasal cavities. The foreign body could not be visualised as both nasal cavities were congested and the mucosa was oedematous. Radiograph showed evidence of a small round metallic object in the left nostril. The child was scheduled for endoscopic removal of the foreign body under general anaesthesia, which was found to be a button battery (Fig. 1 A). Both nasal cavities were filled with mucopurulent greenish discharge and a perforation in the nasal septum was revealed (Fig. 1 B). The nasal septal perforation was managed conservatively due to the young age of the patient. Antibiotics and nasal douches were administered postoperatively. On subsequent 6-month follow-up, the size of septal perforation decreased and the child was asymptomatic.

CASE 2

A 3-year-old girl presented with a history of brownish discharge from the right nasal cavity and nasal obstruction for a period of 3 hours. On examination, a profuse brownish discharge from the right nasal cavity with a metallic foreign body was found. Plain radiograph of the nose revealed a radiopaque foreign body with typical bilaminar structure seen in the right nasal cavity. The foreign body was removed endoscopically under general anaesthesia 2 hours later, and was found to be a button battery that impacted between the right inferior turbinate and nasal septum. There was an extensive mucosal oedema with an area of ulceration and patchy necrosis in the right inferior turbinate and the nasal septum. However, there was no septal perforation (Fig. 2). The child was put on antibiotics after endoscopic removal. Further follow-up after 3 months revealed a healed nasal mucosa with an intact septum.

CASE 3

A 3-year-old girl presented with unilateral nasal pain 2 hours after inserting a foreign body into the left nostril. On examination, a shining metallic foreign body was found

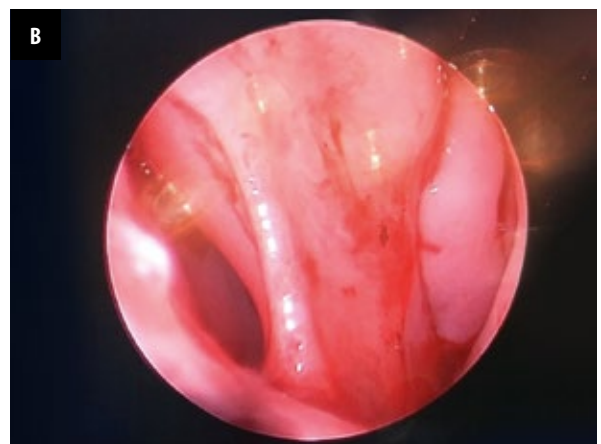
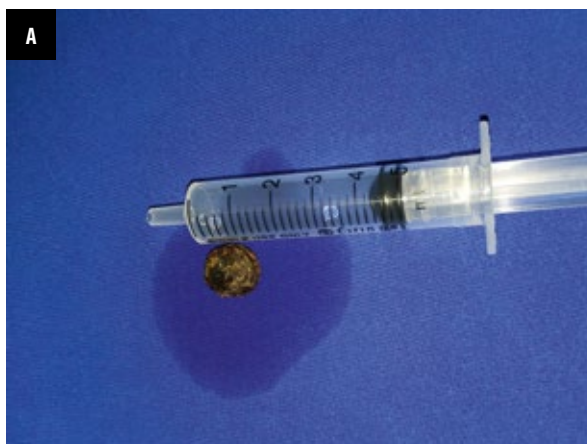
Fig. 1 A. Button battery removed from left nasal cavity; B. An endoscopic view of the left nasal cavity showing anterior septal perforation

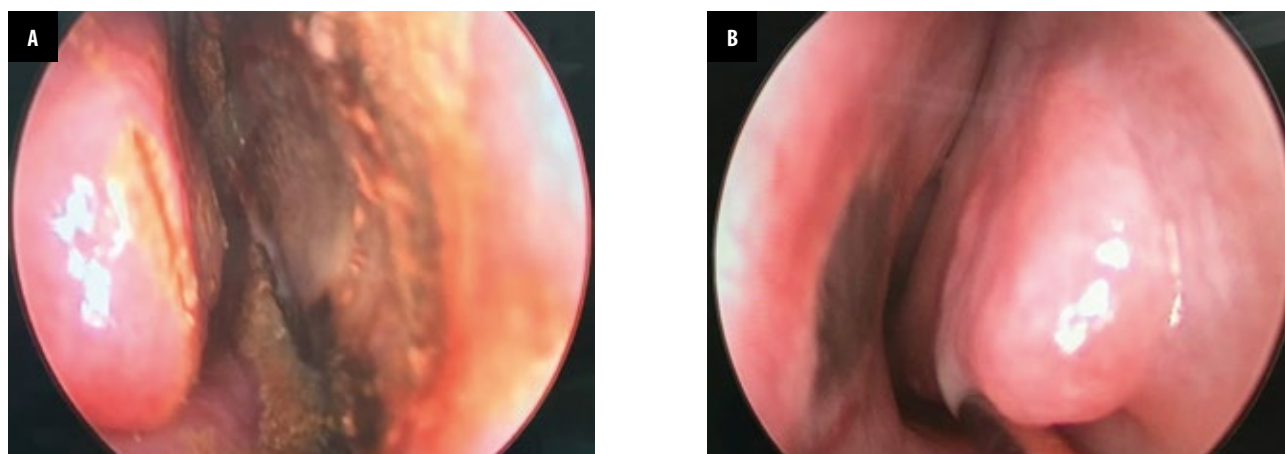


Fig. 2 A. An endoscopic view following removal of the battery showing mucosal ulceration and necrotic area of the right inferior turbinate, middle turbinate and septum; B. Discoloration of the left nasal septum mucosa with no evidence of perforation revealed after removal of button battery

in the left nostril with minimal clear serous discharge. Nasal radiographs (Fig. 3) revealed a radiopaque foreign body in the left nasal cavity with typical bilaminar structure. As the patient was cooperative and the foreign body was easily seen, the removal was done in the clinic without anaesthesia, it was found to be a button battery that impacted between the left inferior turbinate and nasal septum. Endoscopic examination post removal revealed minimal mucosal oedema and ulceration with intact nasal septum. The patient was treated conservatively, and was followed up for a period of 3 months. The nasal mucosa was well healed without any apparent permanent sequelae.

DISCUSSION

Nasal foreign bodies are commonly encountered among children in otorhinolaryngology and emergency departments. Their curiosity about such objects often leads to accidental introduction of foreign bodies into the nose,

especially in children between the ages of 2 and 5 years. Foreign bodies can be classified as either inorganic or organic. Inorganic materials are typically plastic or metal. Common examples include beads, button, stones, paper and small parts from toys. These materials are often asymptomatic and may be discovered incidentally. Organic foreign bodies, including food, rubber, wood, sponge, and metallic batteries, tend to be more irritating to the nasal mucosa, and thus may produce earlier symptoms^(5,6). As benign as nasal foreign body may seem, it harbours the potential for morbidity and even mortality if the object is dislodged into the airway^(5,6).

A button battery owes its name to its shape and size. Recent development in technology has accelerated the broad use of button batteries. They are widely used in daily life and can be easily found in electronic devices, games, toys, calculators, watches, cameras, hearing aids, laser pointers and other electronic instruments. These batteries contain various heavy metals, including mercury, zinc, silver, nickel,

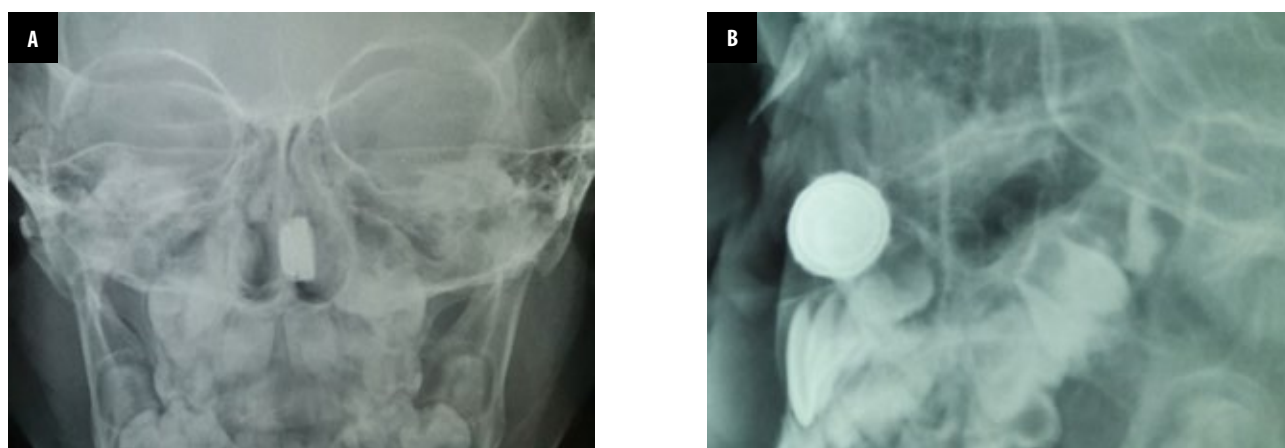


Fig. 3 A. Plain nasal radiograph showed a step-off on anteroposterior view; B. Lateral view of plain nasal radiograph showed "double-ring" or "halo" effect

cadmium, manganese, or lithium, and a concentrated alkaline electrolyte solution of 26% to 45% potassium or sodium hydroxide⁽⁷⁾.

Four mechanisms of mucosal injury have been suggested: 1) leakage of the alkaline contents causing liquefactive necrosis with direct corrosive damage; 2) direct electrical current effects on the mucosa and resultant mucosal burns; 3) pressure necrosis resulting from prolonged local pressure on the tissue; and 4) local toxic effect due to absorption of substances^(4,8,9).

Exudation of tissue fluids caused by a burn injury creates a moist environment. *In vitro* studies have shown that spontaneous leakage of electrolyte solution occurs when alkaline batteries are exposed to moisture. The leaked alkaline electrolyte contents can penetrate deeply into tissues and cause liquefying necrosis, which later results in dissolution of protein and collagen, saponification of lipids, dehydration of tissues, and consequently extensive tissue damage⁽¹⁰⁾. Impaction of nasal button battery can lead to mucosal, turbinate and nasal septal ulceration in 3–6 hours. Inferior turbinate necrosis occurs in 24 hours⁽⁹⁾. Damage to the nasal mucosa has previously been reported after as few as 3 hours, with damage leading to perforation after 7 hours^(1,4). Increased time interval between insertion and removal can lead to devastating complications like septal perforation, mucosal necrosis and synechiae. Ongoing electrical and thermal burning will occur as long as the electrical circuit is intact and, as the length of contact time increases; the chemicals released by erosion of the metal shell of the battery may also contribute to further morbidity⁽¹¹⁾. In this case series, we found that severe nasal mucosal damage and necrosis developed 5 hours after battery lodgement in the nasal cavity and septal perforation was revealed when the duration was longer.

The orientation of the battery in the nasal cavity is also reported to be important, with tissue at the anode pole (negative) more likely to be damaged as the seal or anode pole is the most common site of leakage⁽¹⁾. Hence, if the anode pole is against the septum, perforation is more likely. This can be seen in our case series whereby septal perforation and extensive mucosal damage was found in nasal septum to which the anode side of battery was adhered.

Symptoms and signs range from nasal irritation to pain and burning sensation in the nose, foul smelling profuse brownish nasal discharge and epistaxis. Some children may be asymptomatic due to delayed presentation, while others can develop nonspecific signs like pain, cough, vomiting, irritability, fever, and tachycardia. Unusual presentation in the form of symptoms mimicking acute infection, such as in Case 1, with no clear history of foreign body insertion into the nose, leads to delayed correct diagnosis.

The mainstay of diagnosis is detailed and witness based history, radiological evaluation and diagnostic nasal endoscopy. Foreign bodies can be often detected by anterior rhinoscopy, but on several occasions the mucosal oedema or granulation will obscure it, as in Case 1.

The use of a plain film skull radiograph is advocated in diagnosing every child presenting with a non-visualised nasal foreign body. Button batteries can be easily visualised as radiopaque round objects. Their characteristic radiographic appearance is the bilaminar structure; a double-ring or halo (double-density) in an anteroposterior view and a step-off at the separation between the anode and cathode in a lateral view^(12–14). This radiographic appearance was seen in all of our cases.

An impacted button battery in the nose should be removed immediately. If the foreign body is easily seen and the patient is a cooperative child, it is usually possible to remove the object through the anterior nares without anaesthesia such as in Case 3. Post-removal nasal douching should be performed to wash away the intranasal chemicals.

In the case of anteriorly impacted foreign bodies, apart from manual removal, positive pressure techniques like an ambu bag can be employed. Botma et al. described a technique called “parent’s kiss,” which is mainly used for very small children. In this manoeuvre, the caregiver (usually the parent) blows into the open mouth of the child while occluding the contralateral nostril. This technique is quite effective and less traumatic to the child⁽¹⁵⁾.

However, unskilled attempts to remove a foreign body by personnel without appropriate training may result in a disaster; the foreign body may be displaced backwards and may even reach the nasopharynx with a risk of inhalation. Hence, immediate endoscopic removal under general anaesthesia is advocated especially in the following circumstances: 1) if the patient is uncooperative or very apprehensive; 2) if problematic bleeding is likely, for instance if the foreign body is firmly embedded in granulation tissue; 3) if the foreign body is located posteriorly with a risk of pushing it back into the nasopharynx; 4) if the foreign body is strongly suspected but cannot be found, and a more extensive examination of the nasal cavity is required, with an opportunity to deal with whatever is found⁽²⁾. In cases when the battery resides in the nasal cavity for a longer duration, and thus may be obscured by serosanguinous nasal discharge and crusting, making its removal difficult, removal under general anaesthesia will be necessary⁽¹⁾. In 2 of our cases, we decided to remove button batteries under general anaesthesia because the patient was not cooperative and nasal discharge with crusting obscured the button battery. After removal of the impacted button battery copious irrigation with saline solution should be performed to remove any alkaline precipitates that leaked out of the battery⁽¹⁶⁾. However, in the case of removal without anaesthesia, parents or caretakers should be instructed for proper nasal douching. Intranasal stents can be placed to prevent adhesion and synechiae formation due to severe necrosis.

Nasal septal perforation is one of the most common complications with this type of foreign body. The symptoms vary depending on the size and location. Small perforations refer to those with a diameter of ≤ 0.5 cm; medium perforations have a diameter ranging between 0.5 and 2 cm; large

perforations have a diameter $>2\text{ cm}$ ⁽¹⁷⁾. The symptoms vary in intensity and can affect the quality of patient's life. Septal perforations located anteriorly are more likely to cause discomfort due to turbulent airflow resulting in a variety of symptoms including dryness, crusting, whistling, discharge, epistaxis, nasal obstruction, and pain. Large perforations may result in the loss of support to the dorsum of the nose and subsequent saddle nose deformity. Posterior perforations tend to be less symptomatic compared with anterior perforations due to humidification from the turbinates. Treatment is only necessary for symptomatic perforations. Repeated moistening using antibacterial ointments and nasal douching with saline is sometimes needed to reduce or relieve symptoms of crusting and bleeding. Surgery aimed at correcting nasal septal perforation is based on two main principles: repairing the perforation using mucosal mucoperichondrial and/or mucoperiosteal flaps from the internal nasal cavity, and connective tissue autograft interposed between the mucosal flaps⁽¹⁷⁾. In the case of our patient with nasal septum perforation, the child was asymptomatic; therefore we advocated non-conservative management for the perforation and suggested monitoring for any sign and symptoms. In the paediatric population, reconstructive nasal surgery is typically delayed for as long as possible to allow the nasal structures to fully develop. Operating too soon can have potentially adverse effects on the growth centres of the face, which could lead to further nasal deformity in adult life. Although reports are conflicting, it is generally accepted that the safer route is to wait until the patient has completed puberty before deciding for an operation. Regular follow-up is essential to assess any long-term complications like septal perforation, nasal synechiae, mucosal ulceration and necrosis. The duration of follow-up depends on the severity of mucosal damage and any arising complications. Prevention is the most effective management strategy. Since this condition is more common in children, parents and childcare providers should be educated about the potential hazards associated with battery insertion in the nasal cavity. Devices using such batteries are either kept away from small children or the batteries are secured safely in the product.

CONCLUSION

Button battery as a foreign body in the nasal cavity is a hazardous and should be treated as a life threatening condition due to its electrochemical composition and large potential for extensive tissue damage and complications. Early detection based on detailed history, clinical and radiographic examination, followed by immediate removal is the key in the management. Delayed removal may lead to complications like septal perforation, nasal synechiae, mucosal ulceration and necrosis. Parents and childcare providers should be educated about the potential hazards associated with battery exposure.

Conflict of interest

Authors have no conflict of interest to declare.

References

1. Loh WS, Leong JL, Tan HKK: Hazardous foreign bodies: complications and management of button batteries in nose. *Ann Otol Rhinol Laryngol* 2003; 112: 379–383.
2. Sri Herawati JPB: Impacted button battery in the nasal cavity. *Folia Medica Indonesiana* 2004; 40: 139–142.
3. Lin VY, Daniel SJ, Papsin BC: Button batteries in the ear, nose and upper aerodigestive tract. *Int J Pediatr Otorhinolaryngol* 2004; 68: 473–479.
4. Tong MCF, Ying SY, van Hasselt CA: Nasal foreign bodies in children. *Int J Pediatr Otorhinolaryngol* 1996; 35: 207–211.
5. Jatana KR, Litovitz T, Reilly JS et al.: Pediatric button battery injuries: 2013 task force update. *Int J Pediatr Otorhinolaryngol* 2013; 77: 1392–1399.
6. Hafeez M, Zakirullah I: Foreign body nose in children: a common problem with social roots. *Abasyn University Journal of Social Sciences* 2009; 2: 22–25.
7. Chan YL, Chang SS, Kao KL et al.: Button battery ingestion: an analysis of 25 cases. *Chang Gung Med J* 2002; 25: 169–174.
8. McRae D, Premachandra DJ, Gatland DJ: Button batteries in the ear, nose and cervical esophagus: a destructive foreign body. *J Otolaryngol* 1989; 18: 317–319.
9. Alvi A, Bereliani A, Zahrtz GD: Miniature disc battery in the nose: a dangerous foreign body. *Clin Pediatr (Phila)* 1997; 36: 427–429.
10. Premachandra DJ, McRae D: Severe tissue destruction in the ear caused by alkaline button batteries. *Postgrad Med J* 1990; 66: 52–53.
11. Guidera AK, Stegehuis HR: Button batteries: the worst case scenario in nasal foreign bodies. *N Z Med J* 2010; 123: 68–73.
12. Marom T, Goldfarb A, Russo E et al.: Battery ingestion in children. *Int J Pediatr Otorhinolaryngol* 2010; 74: 849–854.
13. Yardeni D, Yardeni H, Coran AG et al.: Severe esophageal damage due to button battery ingestion: can it be prevented? *Pediatr Surg Int* 2004; 20: 496–501.
14. Srivastava G: Foreign bodies in the oropharynx, gastrointestinal tract, ear, and nose. *Clin Pediatr Emerg Med* 2010; 11: 81–94.
15. Botma M, Bader R, Kubba H: 'A parent's kiss': evaluating an unusual method for removing nasal foreign bodies in children. *J Laryngol Otol* 2000; 114: 598–600.
16. Lee HM, Kim DH, Kim JM et al.: Nasal septal perforation due to button battery. *Journal of Rhinology* 2001; 8: 69–72.
17. Re M, Paolucci L, Romeo R et al.: Surgical treatment of nasal septal perforations. Our experience. *Acta Otorhinolaryngol Ital* 2006; 26: 102–109.